

**The Royal College of Emergency Medicine
&
The Royal College of Radiologists**

Best Practice Guideline

**Diagnosis of Thoracic
Aortic Dissection in the
Emergency Department**



The Royal College of Radiologists



November 2021

Summary of recommendations

1. All clinicians working in the emergency department should be made aware of the difficulties in excluding the diagnosis of TAD and the need to be aware of local policies and resources to assist in this as part of their induction.
2. Each emergency department must have agreed protocols between themselves and their radiology department regarding requests for CT Aortagrams in cases of suspected thoracic aortic dissection.
3. Thoracic aortic dissection is a time critical emergency and provision must be available for the ED to rapidly access CT Aortagrams throughout the whole 24hr period.
4. If the ED suspects a patient has a TAD it is the role of the ED to request the scan and act on the result. This responsibility should not be passed onto another clinical team.
5. All emergency departments should have a local protocol or pathway detailing the actions to be taken once a diagnosis of TAD has been made. This should include details of blood pressure management and local urgent referral pathways to specialist surgical centres, where appropriate.

Scope

Diagnosis of thoracic aortic dissection in adult patients attending the emergency department. The guideline focuses on diagnosis rather than management.

Reason for development

The diagnosis of thoracic aortic dissection (TAD) is often difficult to establish in emergency department (ED) patients attending with chest pain. Key to making the diagnosis is the awareness amongst emergency physicians (EPs) of the need to consider the diagnosis in patients presenting with chest pain. EPs should also have an awareness that TAD can present subtly or in young patients and that their pain may have migrated or dissipated by the time they are seen. Surveillance data suggests that opportunities to diagnose cases of TAD are being missed in the ED, often with catastrophic consequences. This guideline seeks to provide a consensus opinion with regards to which patients should be considered for CT scanning (the diagnostic modality of choice) whilst accepting that this is still an area of considerable controversy and concern.

Introduction

TAD is a relatively uncommon cause of chest pain (acute coronary syndrome is 100-200 times more common) but can be catastrophic with an in-hospital mortality rate of 27% [1]. This makes deciding which patient to request a CT scan on particularly difficult. There are numerous examples of patients attending EDs with chest pain and being discharged without the diagnosis of TAD having been made (Appendix 1).

Risk factors for TAD include hypertension, collagen disorders (Marfan's, Ehler-Danlos), inflammatory vasculitis (giant cell arteritis, Takayasu arteritis, rheumatoid arthritis), instrumentation or structural abnormalities of the aorta (cardiac catheterisation, bicuspid valve, aortic coarctation, valve replacement), pregnancy. Male sex and advancing age are also risks.

Patients with TAD may present with chest pain which is said to be tearing in nature located in the inter-scapular region, however the most discriminating feature of the chest pain is that it is of **sudden onset with its worst severity being at its onset** [2]. Chest pain may occur alone or in combination with back pain, syncope, or new onset neurological deficit. Patients may also present with complications from TAD including myocardial ischaemia, heart failure, pericardial effusion, pleural effusion, renal failure and mesenteric infarction. Clinical findings in TAD may include pulse deficits, aortic regurgitation, unequal blood pressure in both arms, unexplained hypotension or commonly no specific clinical signs.

15% of patients with TAD have a normal chest X-ray (changes suggestive of TAD include widened mediastinum >8cm on a PA film, abnormal (ie. blunted) aortic knob, ring sign [displacement of the aorta >5 mm past the calcified aortic intima], pleural effusion, pleural cap (fluid in the apex of the hemi-thorax), deviation of the trachea & left main bronchus. A normal PA Chest X-ray (CXR) does not exclude or confirm TAD. The main use of a CXR is to exclude alternative causes of chest pain such as pneumonia. It is important that performing a CXR does not delay definitive diagnosis. 30% of patients have a normal ECG [1].

dDimer levels rise abruptly following some types (but not all) of TAD with some evidence to suggest that a level of <500ng excludes the diagnosis (however the false negative rate may be between 4%-18%) [3,4], the causes of elevated dDimers are multiple. Echocardiography may in some settings have a role to play in the diagnosis of TAD; however transthoracic echo (TTE) will miss 30% of dissections, transeosophageal echo is more sensitive than TTE (NPV 99%) [2].

The diagnostic modality of choice is CT Aortogram (CTA) which has high diagnostic accuracy in discriminating the various components of TAD [5]. Initial non-contrast acquisition should form part of the scanning protocol for its value in assessment of intramural haematoma. A post contrast CT of the aorta will delineate the full extent of dissection and involvement of branch vessels. Arterial phase acquisition should routinely be performed with ECG synchronisation (gated scan) with the aim of producing motion-free images of the aortic root. Prospective triggering should be used where possible in order to reduce radiation dose. In low to intermediate risk patients without any abdominal or lower limb symptoms, the coverage should be limited to the thorax in the first instance to limit the radiation dose. If dissection is found to involve the upper abdominal aorta, completion imaging may be required. Extended coverage to include the whole aorta is necessary from the very beginning in high risk patients or those with known aortic disease.

Emergency department access to CT scans is key to the rapid diagnosis and institution of appropriate management. Ensuring there are minimum barriers to CT scans includes ensuring EPs consider the diagnosis in appropriate cases and local protocols are in place for urgent CT scans meeting the appropriate criteria. Centres that have successfully addressed their TAD missed diagnosis rate by implementation of awareness raising programmes and increased access to CTA have reported a 3% pickup rate for TAD and 42% pickup rate for alternative diagnoses [6]. It is worth reflecting that the diagnostic yield of CTPA for pulmonary embolus varies between 4.7 to 31% [7] and the diagnostic yield of a potentially neurosurgical lesion CT head scan in patients with minor head injury (NICE indications) is only 3% [8].

TAD is a time critical emergency and provision must be available for the ED to rapidly access urgently reported CTAs throughout the whole 24hr period.

Recommendations

All clinicians working in the ED should be made aware of the difficulties in excluding the diagnosis of TAD and the need to be aware of local policies and resources to assist in this as part of their induction. Teaching about the pitfalls of presentation and diagnosis, along with regular shop floor discussion (board rounds etc.) are key to raising awareness.

For patients presenting to the emergency department with chest pain, a CTA should be requested if any of the high risk features below are present or in the case of more than one high risk feature from different boxes a CTA whole aorta UNLESS another cause of the chest pain is clearly identified and evidenced eg. acute myocardial infarction, pneumothorax, pulmonary embolus etc.

High Risk CONDITIONS	High Risk Pain FEATURES	High Risk CLINICAL FINDINGS
Marfan syndrome Connective tissue disease Family History Aortic Disease Known aortic Valve Disease Recent Aortic Manipulation Known thoracic aortic aneurysm	Chest, back or abdominal pain described as: ABRUPT in onset / severe in intensity Or Ripping/tearing/sharp or stabbing quality radiating to back	Pulse deficit Systolic BP differential (>20mmHg) Focal neurological deficit (in conjunction with pain) Aortic regurgitation murmur (new or not known and with pain)

For patients presenting with chest pain who do not have any high risk features listed above, further investigation should occur along standard lines. In the event of diagnostic uncertainty the decision to proceed to CTA should be taken by a senior emergency medicine clinician taking into account the clinical history, examination and investigation results.

If the ED suspects a patient has a TAD it is the role of the ED to request the scan and act on the result, this responsibility should not be passed onto another clinical team.

All emergency departments should have a local protocol or pathway detailing the actions to be taken once a diagnosis of TAD has been made. This should include details of blood pressure management and local urgent referral pathways to specialist surgical centres, where appropriate.

Authors

Professor Mark Callaway, Medical Director, Professional Practice, Clinical Radiology at the Royal College of Radiologists, Emma Redfern (Chair) Safer Care Committee RCEM, James France (Chair) Best Practise Committee RCEM.

Acknowledgements

Written in collaboration with the Royal College of Radiology Professional Standards and Support Board and RCEM QEC Committee, Baljinder Singh

Review

Usually within three years or sooner if important information becomes available.

Conflicts of Interest

ER is a non-paid medical advisor to the charity Aortic Dissection Awareness

Disclaimers

The College recognises that patients, their situations, Emergency Departments and staff all vary. This guideline cannot cover all possible scenarios. The ultimate responsibility for the interpretation and application of this guideline, the use of current information and a patient's overall care and wellbeing resides with the treating clinician.

Research Recommendations

NCEPOD should undertake a national review of all TAD deaths.

Incidence of pulse deficits and unequal blood pressure in non-chest pain population.

The role of dDimer as a screening test for TAD in ED patients presenting with chest pain and ECG finding not consistent with infarction or ischaemia.

Audit standards

None

Key words for search

Thoracic aortic dissection, acute aortic syndrome, aortic dissection

References

1. Hagan PG et al. The International Registry of Acute Aortic Dissection (IRAD). New Insights Into an Old Disease. *JAMA* 2000, 283; 7: 897-903
2. European Society Cardiology Guidelines on the diagnosis and treatment of aortic diseases. *European Heart Journal* 2014, 35; 2873-2926
3. Hazui H, et al. Simple and useful tests for discriminating between acute aortic dissection of the ascending aorta and acute myocardial infarction in the emergency setting. *Circ J.* 2005;69(6):677
4. Paparella D, et al. D-dimers are not always elevated in patients with acute aortic dissection. *J Cardiovasc Med (Hagerstown)*. 2009;10(2):212
5. Vardhanabhut V et al. Recommendations for accurate CT diagnosis of suspected acute aortic syndrome (AAS) –on behalf of the British Society of Cardiovascular Imaging (BSCI)/British Society of Cardiovascular CT (BSCCT). *Br J Radiol* 2016,89;20150705
6. Redfern E. Personal communication May 2021
7. Deblois S, Chartrand-Lefebvre C, Toporowicz K, et al. Interventions to reduce the overuse of imaging for pulmonary embolism: a systematic review. *J Hosp Med.* 2018;13:52–61
8. Foks K A, van den Brand C L, Lingsma H F, van der Naalt J, Jacobs B, de Jong E et al. External validation of computed tomography decision rules for minor head injury: prospective, multicentre cohort study in the Netherlands *BMJ* 2018; 362 :k3527
9. Stepinska J et al. Diagnosis and risk stratification of chest pain patients in the emergency department: focus on acute coronary syndromes. A position paper of Acute Cardiovascular Care Association. *European Heart Journal* 2020, 9(1); 76-89
10. Black JH, Manning WJ. Clinical features and diagnosis of acute aortic dissection. *UptoDate.com* accessed April 2021.

Appendix 1

Examples of selected cases of Missed Thoracic Aortic Dissection in the Emergency Department from a 10 year period to date

Case #1

39yr man, known hypertension and smoker presents to the ED with chest pain. Chest pain -severe, sharp, central chest pain, radiating to the left side of his chest, left shoulder and half way down his left bicep. His pain was noted to have been exacerbated by movement or left arm straining, and he was discharged home with a diagnosis of musculoskeletal injury with a plan for analgesia and instructions to return if his symptoms worsened. Normal ECGs, negative dDimer and Troponin.

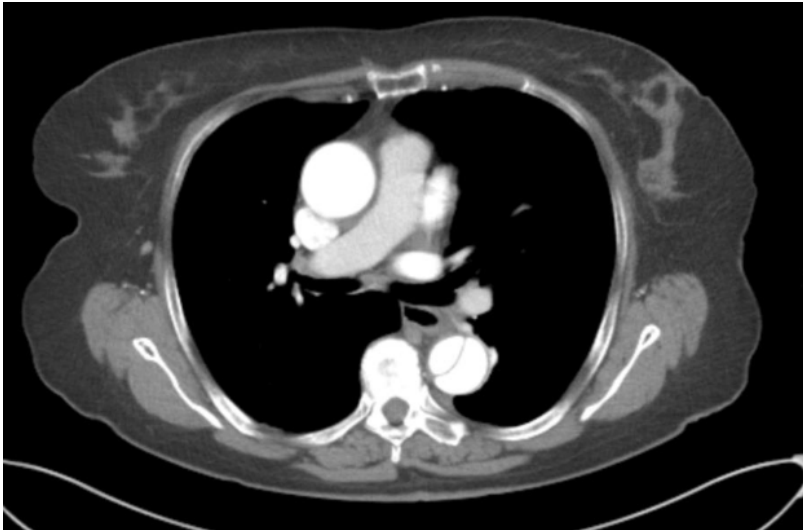
He returns 5 days later the Emergency Department SHO recorded that he complained of sudden onset chest pain, which radiated through to his back, whilst lying on his sofa. The pain was described as severe and constant, and he had vomited 3 times. A diagnosis of gastritis or pericarditis was made by the ED and the patient treated with morphine, omeprazole and IV fluids. Patient referred to the medical team, normal amylase and troponin. Seen by medical team, thought differential diagnosis not unreasonable but noted Bilateral BPs as 174/109 mmHg (left arm), and 147/107 mmHg (right arm). Discharged home, returned 1 day later in cardiac arrest and was unable to be resuscitated.

Case #2

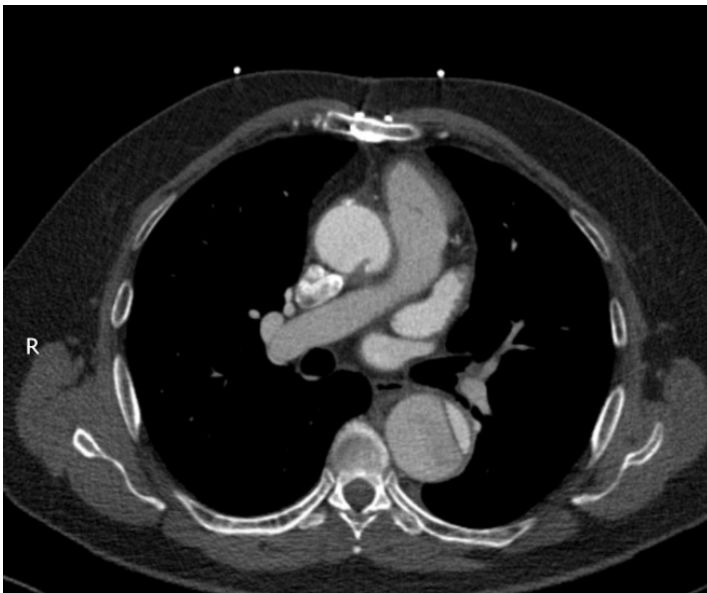49-year-old presented at the ED with non-radiating, stabbing chest pain and was 8/10 in severity at the onset. He reported that his vision went cloudy and he felt SOB but was not sweaty or clammy. The severity of the pain was 3/10 after receiving IV morphine, aspirin and GTN. He smoked 20 cigarettes per day but there was no other medical or drug history. He scored 0 on NEWS 2 and his two high sensitive troponin levels were 9.4ng/L and 9.7ng/L (no significant change between the two samples taken 3 hours apart). The ECG was NSR with T- wave inversion in Lead 1, AVL, V4, V5 and V6. The blood results were normal except that his WCC was 12.5 and D-Dimer was 1592. Chest X-ray was clear. He was referred to the medical team with a diagnosis of possible pulmonary embolism (PE) and treated with enoxaparin. The case was discussed with the Medical Registrar and the patient was discharged with a plan to return the next day for a CTPA via the AEC. NEWS2 score zero for the preceding 3 hours. Ten minutes after discharge he suffered a cardiac arrest and was unable to be resuscitated.

Appendix 2

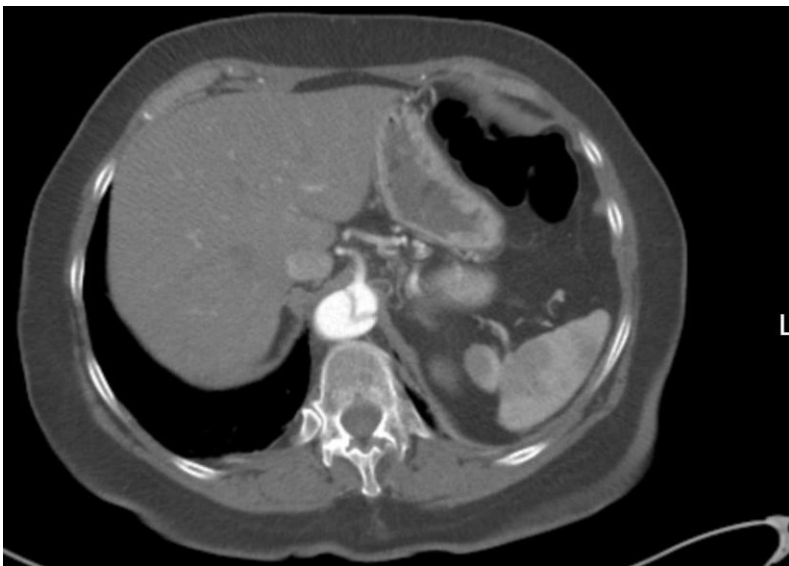Examples of CT findings in thoracic aortic dissection



Post contrast CT Aorta showing descending thoracic aortic dissection



Pre contrast CT Aorta showing ascending and descending thoracic aortic dissection



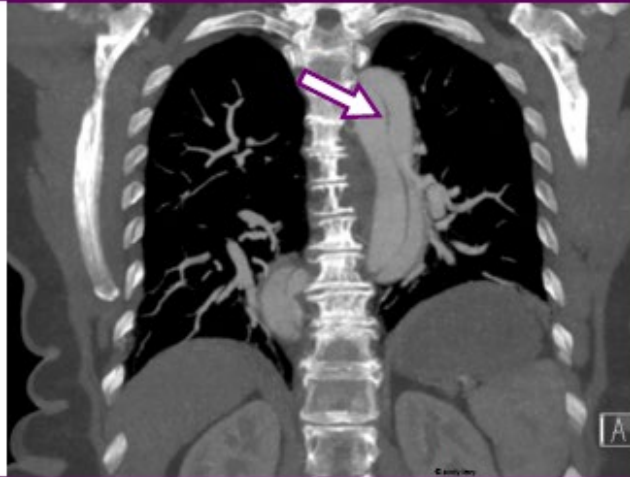
Post contrast CT Aorta showing descending thoracic aortic dissection



The Royal College of
Emergency Medicine

March 2016

Safety Alert: Missed aortic dissection



Sudden chest pain, maximal at onset?

Particularly if it radiates to the back, think aortic dissection

- Patients feel very unwell or collapse
- The pain can vanish then recur in the epigastrium, *or elsewhere*
- Blood tests can be normal
- ECG and CXR can be normal
- The only way to make the diagnosis is by CT scan

For other RCEM issued Safety Alerts and Safety Newsflashes see:
www.rcem.ac.uk/Shop-Floor/Safer%20Care

Unexplained Severe Pain?

THINK AORTA

Aortic Dissection is an emergency
that is often fatal when missed

CT Scan for a definitive diagnosis

Symptoms

- Pain is the #1 symptom
- Neck, back, chest or abdomen
- Numbness or weakness in any limbs
- History of collapse

Pain characteristics can be:

- Maximal in seconds
- Migratory & transient
- Pain can be sharp, tearing, ripping

Patient Risk Factors

- Hypertension
- Aortic aneurysm
- Bicuspid aortic valve
- Familial aortic disease
- Marfans and other connective tissue disorders

Physical Examination

- Pulse deficit or vascular signs
- Neurological signs of stroke or paraplegia

Diagnostic Warning

- Chest x-ray, ECG, ultrasound & blood tests can be normal

Aortic Dissection Awareness UK in collaboration with:

Heart Research UK
Society for Cardiothoracic Surgery in Great Britain and Ireland
The Royal College of Emergency Medicine

www.thinkaorta.org





Royal College *of*
Emergency Medicine

The Royal College of Emergency Medicine

7-9 Breams Buildings

London

EC4A 1DT

Tel: +44 (0)20 7400 1999

Fax: +44 (0)20 7067 1267

www.rcem.ac.uk

Incorporated by Royal Charter, 2008

Registered Charity number 1122689

Excellence in Emergency Care