

Paediatric trauma protocols

Contents

Foreword	3	Appendix 1. General considerations and recommendations that will ensure patient safety is of the highest priority during imaging	20
Executive summary	4		
Standard of care	6	Appendix 2. Camp bastion contrast calculator	22
Incidence and pattern of paediatric trauma	7		
Ionising radiation considerations	10	Appendix 3. Acute primary assessment report for paediatric CT with major trauma	23
Choice of imaging modality	11	Appendix 4. Emergency department paediatric major trauma imaging decision tool	24
Conclusion	16		
References	17		

Foreword

The Royal College of Radiologists (RCR) would like to thank and acknowledge the contribution to this important publication of the RCR's Faculty of Clinical Radiology, the Professional Support and Standards Board and, in particular, the individual contribution of Judith Foster, Paediatric Radiologist who has led and chaired this working party.

We also wish to thank the following members of the working party who have all contributed to the development this document: Mark Lyttle, Consultant in Paediatric Emergency Medicine; Karl Johnson, Paediatric Radiologist; Jo Danin, Paediatric Radiologist; Sam Negus, Paediatric Radiologist; John Somers, Paediatric Radiologist; Chris Fitzsimmons, Consultant in Paediatric Emergency Medicine; Ross Fisher, Consultant

Paediatric Surgeon; Caren Landes, Paediatric Radiologist; and Nicholas Ashford, Consultant Radiologist and RCR Officer. We would also like to thank Dr Tony Kehoe (Emergency Department Consultant) and Dr Richard Miles (Consultant Interventional Radiologist) for providing the decision tool and the Camp Bastion contrast wheel respectively; and Matt Dunn, Head of Radiation Physics for his help in producing this guidance.

We would also like to thank the Royal College of Paediatrics and Child Health for its input and the Trauma Audit and Research Network (TARN) for its help in providing data on paediatric trauma.

Dr Pete Cavanagh
Vice-President
Faculty of Clinical Radiology

This document has been endorsed by



The College of
Emergency Medicine

Executive summary

Children are different – they are not just small adults.

What defines a child? What is severe trauma in relation to a child? How should a child with severe trauma be imaged? These are simple questions but the answers are complex. Childhood covers the period from birth through adolescence to adulthood and thus there can be no one size fits all answer to how a particular child with a particular injury should be imaged. For example, injuries regarded as common and serious in the adult population such as spinal or pelvic injury are exceedingly rare in pre-adolescent children. Injuries regarded as life-threatening in the adult population (for example, liver and spleen trauma) are routinely managed conservatively in children. In addition, it has recently become increasingly clear that the cancer

risk of computed tomography (CT) in childhood is real, significant and is higher in younger ages.

The following guidelines will assist radiologists and clinicians dealing with a severely injured child to base imaging decisions on the best available evidence. The emphasis is on careful, competent clinical evaluation and knowledge of injury patterns in children of various ages, judicious use of plain radiographs and targeted use of CT with relevant paediatric protocols. The use of adult protocols and in particular the 'whole-body' CT trauma survey is not appropriate as a routine investigation in childhood.

Dr John Somers

Dr Nicholas Ashford

Dr Judith Foster

Introduction

This document should be read in conjunction with the RCR's *Standards of practice and guidance for trauma radiology in severely injured patients*.¹ Where there is a perceived discrepancy this paediatric document should take precedence for patients under 16 years of age.

The intended purpose of the paediatric guidelines is to recognise the different physiological and anatomical considerations of the growing child and to highlight the different approach to imaging needed. The decision-making in imaging injured

paediatric patients should always be underpinned by clinical discussions at a senior level between radiologists, emergency physicians and other relevant subspecialties.

This document will discuss the relevant indications and appropriate imaging for each anatomical region. Variations dependent on age will be highlighted.

Standard of care

All children, regardless of age, who are admitted to a paediatric major trauma centre or paediatric trauma unit, should expect to receive a high standard of appropriate and timely care. The wellbeing and safety of the patient are paramount and this is never more so than when dealing with an injured child. This relates both to clinical management and any radiological imaging. All imaging should be appropriate to the child's age

and clinical condition and be reported by a suitably trained radiologist. Exposure to ionising radiation should always be kept to a minimum and the 'as low as reasonably achievable' (ALARA) principles should be adhered to. The 'routine' use of adult trauma protocols is inappropriate. General considerations for prioritising patient safety are included in Appendix 1.

Incidence and pattern of paediatric trauma

The incidence of paediatric major trauma within the UK is low when compared with adults. A retrospective analysis of paediatric data from the Trauma Audit & Research Network for the year beginning 1 April 2012, corresponding to the introduction of the National Trauma Networks in England, clearly illustrates this point.²

The total number of individuals aged 16 years and above admitted to hospitals in the UK and submitted to TARN was 36,369 and there were

2,409 children under 16 years (Table 1).² While the national paediatric trauma workload is relatively low, the majority of children in this 12-month period were initially conveyed to predominantly adult-orientated centres (Table 2, Figure 1).² For these children, initially seen at an adult major trauma centre (MTC), a combined adult and paediatric MTC or a trauma unit (TU), it is important that appropriate paediatric management pathways are in place.

Table 1. The total number of individuals aged 16 years and above admitted to hospitals in the UK²

Age band	Isolated head		Isolated face		Isolated chest		Isolated abdo		Isolated extremity		Isolated external		Multiple injuries		None		Total	
	Pts	%	Pts	%	Pts	%	Pts	%	Pts	%	Pts	%	Pts	%	Pts	%	Pts	%
Under 1	161	42%	0%	14	4%	5	1%	114	30%	0%	26	7%	61	16%	381	100%		
1-5	154	20%	0%	23	3%	15	2%	506	65%	0%	41	5%	42	5%	781	100%		
6-11	129	21%	0%	25	4%	43	7%	279	46%	0%	54	9%	76	13%	606	100%		
12-15	155	24%	0%	39	6%	56	9%	206	32%	0%	58	9%	127	20%	641	100%		
16 & over	8700	24%	24	0.07%	4652	13%	1305	4%	10142	28%	40	0.11%	3199	9%	8307	23%	36369	100%
Grand total	9299	24%	24	0.07%	4753	12%	1424	4%	11247	29%	40	0.10%	3378	9%	8613	22%	38778	100%

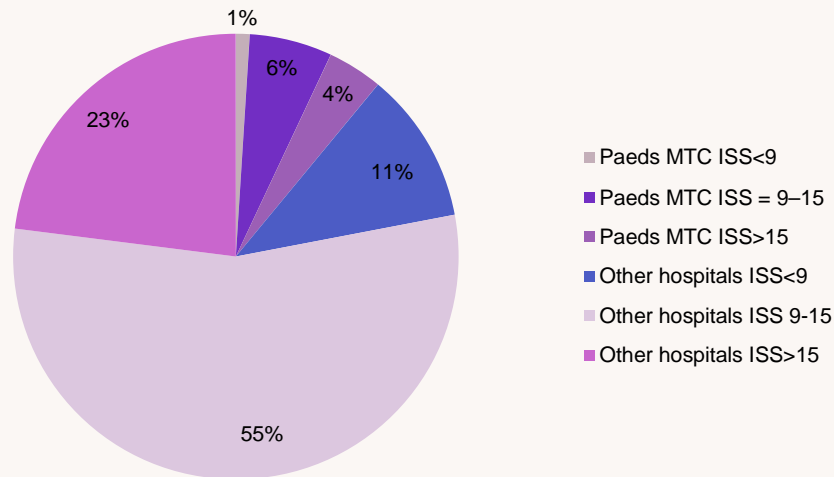
Sites: all UK hospitals; Date range: 01/04/2012–31/03/2013. Admission type: All – direct and unmatched transfers in; Age limit: None; Grouping: Body area of AIS 3+ severity injuries

Table 2. Number of children seen in an MTC vs other type of hospital²

Age band	Paeds MTC			Other hospitals		
	ISS<9	ISS = 9-15	ISS>15	ISS<9	ISS = 9-15	ISS>15
Under 1	5	12	18	50	118	99
1-5	4	38	20	29	476	101
6-11	8	41	16	53	263	123
12-15	9	28	24	92	237	143
16-19			1	236	463	539
Grand total	26	119	79	460	1557	1005
Total aged 0-16	26	119	78	224	1094	466
% aged 0-16	1%	6%	4%	11%	55%	23%

Sites: all UK hospitals; Date range: 01/04/2012–31/03/2013. Admission type: Direct; Age limit: <20 years; Grouping: Hospital type, ISS band

Figure 1. Percentage of patients by ISS group treated by one of the four standalone paediatric MTC vs all other hospitals²



A review of the present CT imaging practice between mixed and stand-alone paediatric centres does suggest some variation in practice. Those children who required a CT were more likely to have multiple areas scanned if they were imaged in a mixed MTC rather than a stand-

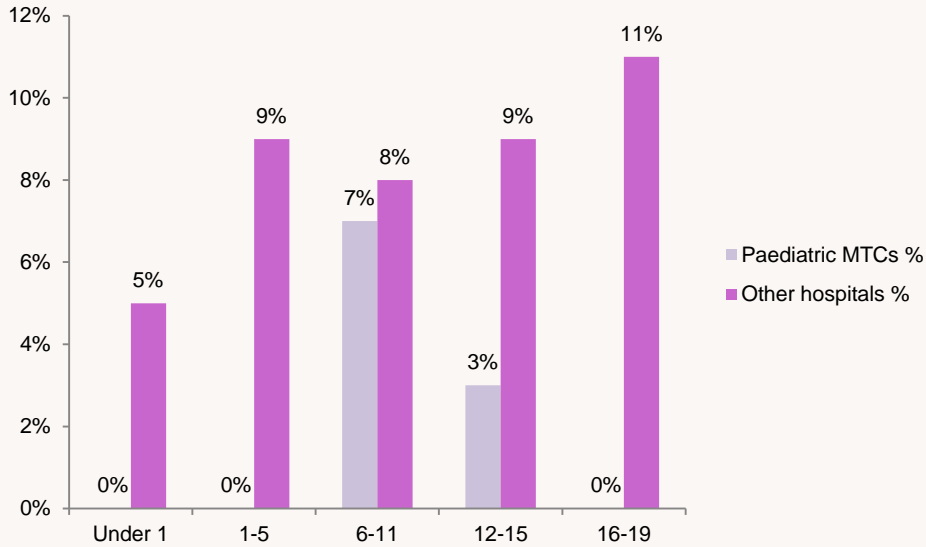
alone paediatric MTC. For those children undergoing CT scan in a paediatric MTC in England, only 3% had a full body CT compared with 9% in an adult unit Table 3, Figure 2.² This practice variation reflects previous reports from the USA.^{3,4}

Table 3. Number of all directly admitted patients with CT within four hours of emergency department arrival that had a full body scan in this timeframe²

Age band	Paediatric MTCs			Other hospitals			Total		
	Patients with full-body CT within 4 hours	All patients with CT within 4 hours	Percentage	Patients with full-body CT within 4 hours	All patients with CT within 4 hours	Percentage	Patients with full-body CT within 4 hours	All patients with CT within 4 hours	Percentage
Under 1	0	18	0%	4	85	5%	4	103	4%
1-5	0	26	0%	11	120	9%	11	146	8%
6-11	2	28	7%	14	173	8%	16	201	8%
12-15	1	35	3%	19	223	9%	20	258	8%
16-19				82	778	11%	82	778	11%
Grand total	3	107	3%	130	1379	9%	133	1486	9%

Sites: all UK hospitals; Date range: 01/04/2012–31/03/2013. Admission type: Direct with CT within 4 hours of ED arrival; Age limit: <20 years; Grouping: Hospital type, CT type within 4 hours; Description: The number of patients with CT within 4 hours of emergency department arrival that had a full body scan in this timeframe.

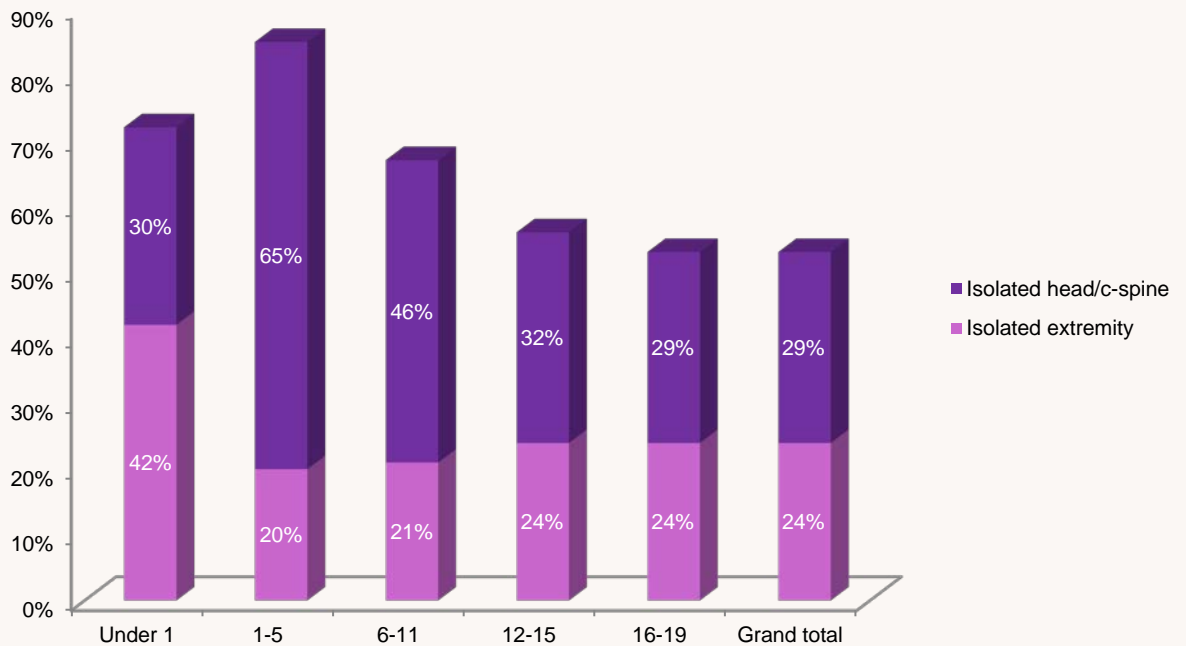
Figure 2. Percentage of all directly admitted patients with CT within four hours of emergency department arrival that had a full body scan in this timeframe²



The hospital data submitted to TARN shows that in the majority of paediatric cases injuries were mainly of the extremities, and to a lesser extent the head and cervical spine. The injury pattern in

children is typically to an isolated anatomical area rather than multiple sites (Table 1, Figure 3).² It is important to appreciate this pattern of potential injury when considering the need for imaging.

Figure 3. Percentage of TARN patients, by age group, that have an isolated head/c-spine or extremity* injury, with an AIS \geq 3²



* Extremity groups all four limbs as one body area; ie, a patient can have injuries to more than one limb

Ionising radiation considerations

A number of recent publications have highlighted the fact that there is no safe lower level of radiation exposure.⁵⁻⁸ The increased risk from ionising radiation in children is due to a number of factors. Developing and maturing tissues in the growing child are more radiosensitive, there is a cumulative radiation risk over a lifetime, and they have a longer lifetime in which to express the increased relative risk.^{9,10} These factors emphasise the need to adhere to the ALARA principle. Within the United States, there is an

increasingly influential Image gently campaign,¹¹ which advocates reducing ionising radiation in children.

Using the ALARA principle in a trauma setting, the initial clinical question needs to be: 'Does this child need imaging at all?' If imaging is required, further questions should be asked in regards to which anatomical areas need to be covered, and whether primary imaging should be plain radiographs or an alternative modality such as CT.

Choice of imaging modality

In the acute paediatric trauma setting there is currently no role for ultrasound outside of assisting in interventional procedures. The RCR Guidelines for the severely injured patient (2010) state that 'Focused Abdominal Sonography in Trauma (FAST) does not offer any additional information to that obtained with a CT scan¹ and should not be performed if it would delay transfer to CT' with studies demonstrating negative predictive values of only 50–63% in unstable patients.^{12,13} This document focuses on adult patients but abdominal ultrasound has also been shown to have only modest sensitivity in detecting haemoperitoneum in children.¹⁴

In the acutely injured child, magnetic resonance (MR) imaging is primarily reserved for potential spinal cord injury, though it is acknowledged that access to MR imaging may be difficult.

The most appropriate imaging modality will be covered in more detail within this document by anatomical area. The value of a normal radiograph for specific areas must not be underestimated. Discussion between a senior radiologist and emergency physician about the radiographic findings may be all that is necessary to exclude significant injury and obviate the need for further imaging. All imaging pathways for suspected injury must rely on robust clinical observation as their starting point.

If CT is deemed the most appropriate investigation, appropriate dose reduction procedures must be in place. All CT manufacturers have dose reduction software and these should be used to their full extent. If possible the use of more advanced iterative reconstruction software applications should be made available. These reconstructive algorithms may add considerable delay in producing the

definitive image and this should be taken into account, and balanced with the clinical situation. Significant dose reduction can be achieved in paediatric patients without any loss of diagnostic information by the use of judicious kilovolt and milliampere reduction.¹¹

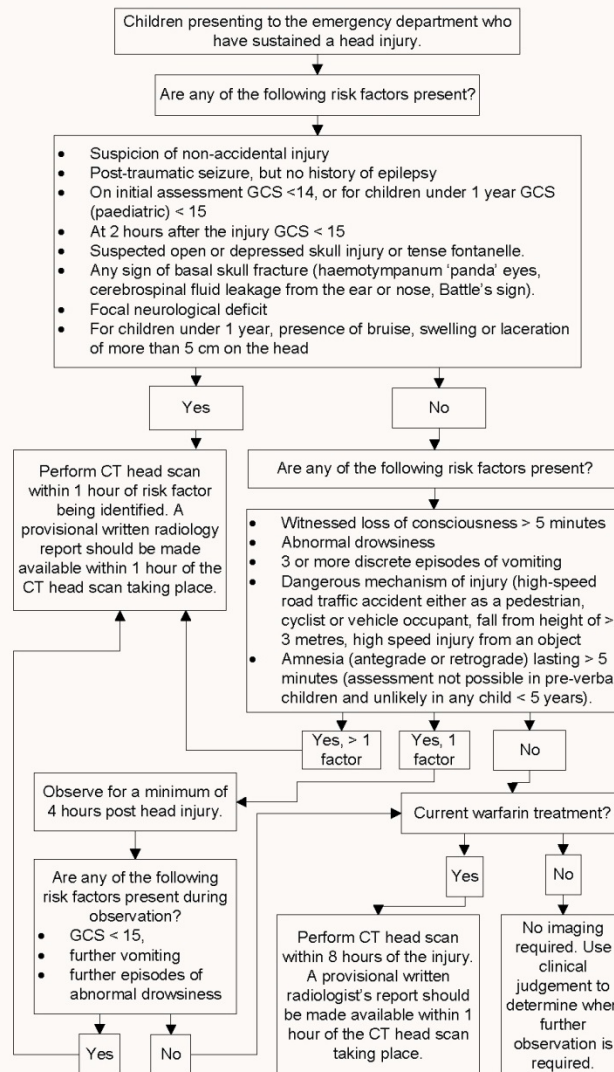
Cranial imaging

CT is the primary investigation for cranial imaging in the child who has suffered head trauma. It displays high sensitivity and specificity for identification of traumatic brain injury and is readily available in most centres. However the dose of ionising radiation required for cranial CT has been demonstrated to be associated with an increased incidence of cancer and it should not be used for all children with head injury. The indications for cranial imaging have therefore been evaluated by the National Institute for Health and Care Excellence (NICE)¹⁵ and are summarised in the algorithm presented as Figure 4.

All children with head injuries should be assessed by an appropriately trained professional within 15 minutes of hospital presentation, and immediately if there is any reduction in conscious level. Adequate resuscitation, clinical examination and administration of analgesia should take place in the process of deciding whether to perform CT.

Isolated head injuries are common in childhood and fulfilling the criteria for a cranial CT scan is not an indication on its own for a CT of the cervical spine or any other body part.

Cranial CT should be performed before administration of intravenous contrast. Following the ALARA principle, avoidance of the lens should be optimised.

Figure 4. Selection of children for a CT head scan¹⁵

National Institute for Health and Care Excellence. *CG 176 Head Injury: Triage, assessment, investigation and early management of head injury in children, young people and adults*. London: NICE, 2014. Reproduced with permission.

Cervical spine imaging

Paediatric cervical spine injury is uncommon.^{16,17}

Appropriate clinical evaluation must be undertaken before imaging is performed as it is an anatomical area that is relatively radiosensitive. Prior to cervical spine imaging a full history and examination must be performed where possible, with any imaging being complementary to other features elicited. Imaging should not be used in isolation as a diagnostic measure.

The criteria employed in the 2014 NICE guideline (CG176) for determining whether cervical spine imaging is required is extrapolated from a clinical

decision rule that was originally derived for adults; the Canadian C-spine rule.¹⁸ Figure 5 shows the process for the selection of children for imaging of the cervical spine.¹⁵ It should be noted that the algorithm presented is extracted from NICE guideline CG176 which refers primarily to management of head injury – presence of head injury alone is not sufficient to enter the starting point of the algorithm; rather there must be clinical suspicion (based on history or examination) of potential cervical spine injury.

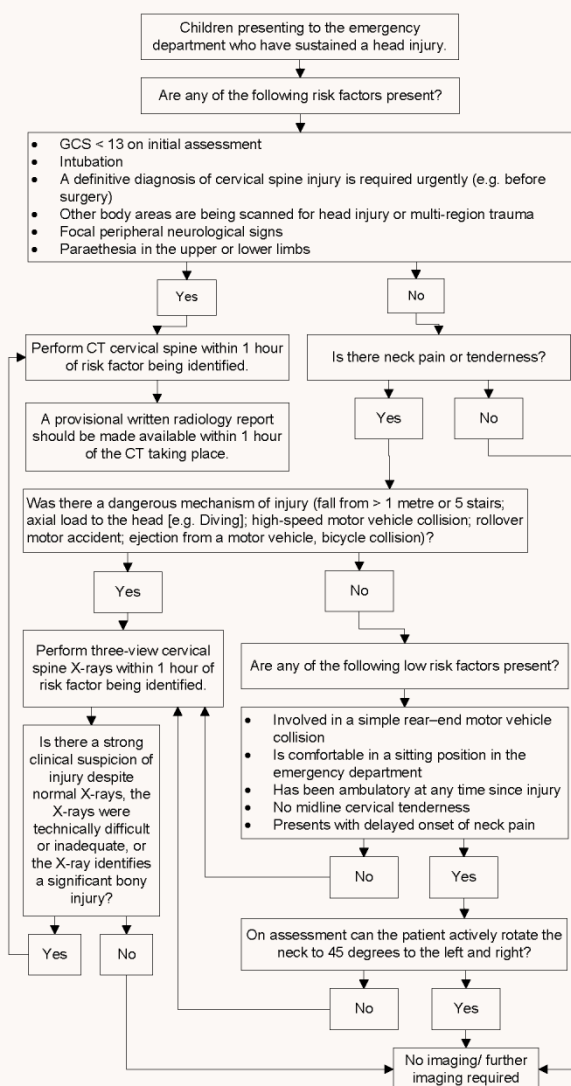
Initial imaging of the cervical spine may be with plain radiographs or CT scan depending on the clinical situation. Where plain radiographs are

indicated, an adequate cervical spine series must include (i) lateral cervical spine X-ray to include the base of skull and the junction of C7 and T1, (ii) Anteroposterior cervical spine x-ray to include C2 to T1 and (iii) an adequate peg view if attainable. Peg views may be difficult in young children. However it is recommended that if they can obey commands and open their mouth a peg view should be attempted.¹⁵ Adequate radiographs of the cervical spine may exclude

significant bony injury and obviate the need for CT.

In a stable child undergoing cranial CT, discussion between senior radiologists and senior clinicians as to the most appropriate imaging of the neck (where clinically indicated) is advised. It is inappropriate to perform cervical spine imaging automatically when performing cranial imaging without appropriate discussion.

Figure 5. Selection of children for imaging of the cervical spine¹⁵



National Institute for Health and Care Excellence. *CG 176 Head Injury: Triage, assessment, investigation and early management of head injury in children, young people and adults*. London: NICE, 2014. Reproduced with permission.

Imaging the spine

Potential spinal injuries should be assessed on a case-by-case basis with appropriate imaging guided by discussion with the radiologist where clinical condition allows.

General principles

- Clinical assessment should underpin investigations
- Plain radiographs of the injured region will generally be the primary investigation.

- Targeted CT of an area may be required for further assessment.
- CT of the lumbar spine is included in CT of the abdomen and pelvis.
- Where there are definitive neurological signs, the primary imaging modality should be MR where possible.

Imaging the chest

- The primary investigation for blunt chest trauma is the chest X-ray. This will detect pneumothorax, haemothorax, rib fractures, gross mediastinal abnormalities, diaphragmatic injuries and rib fracture.^{19–22}
- Penetrating trauma is an indication for contrast-enhanced chest CT due to the incidence of occult vascular injury.
- Further imaging in blunt chest trauma should be dictated by the nature of the trauma, the clinical condition of the child and the initial radiographic findings.
- In the following patients CT can be obviated as it is unlikely to lead to a change in management:²³
 - The chest film is normal
 - The patient is conscious
 - The patient is clinically stable.

Thoracic spine

If there is a high index of suspicion of thoracic spine injury, plain films and MRI are recommended.²⁴ If MRI is not acutely available, localised CT of the affected area should be performed.

Imaging the abdomen

- Where clinically indicated contrast-enhanced CT is the modality of choice for the assessment of acute traumatic intra-abdominal injury.^{25–28}
- Single-volume dual-contrast CT of the abdomen is advised to minimise radiation burden.
- An example of a suitable contrast and timings calculator is included (see the Camp Bastion contrast wheel, Appendix 2).
- A hand injection of contrast is appropriate in very small children and babies.

- There are no mechanisms of injury which mandate abdominal CT as an isolated factor. Decisions to perform abdominal CT should be made on the basis of the clinical history and examination.²⁹
- Where there is an isolated head injury, a reduced Glasgow Coma Scale (GCS) score should not be the only justification for abdominal CT. The decision to perform abdominal CT should be made on the basis of the clinical history and examination.
- Special consideration may need to be given to those children who are intubated prior to hospital assessment or who require transfer to another centre.
- The following clinical variables have been found to be associated with intra-abdominal injury and may indicate the need for abdominal CT:^{30,31}
 - Lap belt or handle bar injuries
 - Abdominal wall ecchymosis
 - Abdominal tenderness in a conscious patient
 - Abdominal distension
 - Clinical evidence of persistent hypovolaemia; for example, persistent unexplained tachycardia
 - Blood from the rectum or nasogastric tube.
- Abdominal injuries are rare where there is neurological impairment in the absence of abdominal signs and symptoms.³²
- The effect of CT information has been documented to have an effect on management plans and monitoring of patients.³³
- A normal CT strongly predicts the lack of subsequent deterioration of a patient's condition.³³

Imaging limbs

- Using the clinical history and examination, clinicians should request plain radiographs of the injured region as the primary investigation.
- This will usually be anteroposterior and lateral views including the adjacent joints.
- CT may be required for complex fractures.

Imaging the pelvis

- Pelvic fractures are rare in children.
- A screening pelvic radiograph is not indicated in all cases.^{34–36}
- Pelvic imaging should only be considered if there are concerns after clinical assessment.
- The presence of a pelvic brace is not an indication in isolation for imaging without prior clinical assessment.
- Pelvic fractures can be associated with multi-organ injuries. The bony pelvis will be included on CT evaluation of the abdomen and pelvis. Where clinically indicated, contrast-enhanced CT of the abdomen and pelvis is the modality of choice.

CT dose optimisation

- Use scan parameters – mA, kVp and pitch according to a patient's weight or age.³⁷

- There should be an acceptable level of noise for 'trauma scanning'.
- Single-phase acquisition with a dual contrast model – see Appendix 2. Camp Bastion contrast wheel.
- Use iterative reconstruction, tube current modulation or organ-based modulation where available.³⁸
- Use protocols to reduce dose to particularly radiosensitive areas, for example, lens, where possible.
- Use of breast and thyroid shields should be considered.

Interventional radiology

Paediatric patients who require interventional radiology should be treated in a dedicated tertiary referral centre by an expert in interventional radiology with appropriate skills where possible.

Conclusion

This document provides clear evidence based guidance for those involved in imaging decisions for paediatric trauma. Injury patterns in children differ vastly to those in adults; this important factor must be taken into account. The need to keep radiation dose as low as possible while still providing good quality examinations is paramount. Evidence-based guidance has been given regarding appropriate imaging protocols and particular note should be made of:

- The template for acute primary assessment report for paediatric CT with major trauma (Appendix 3)
- The Camp Bastion contrast calculator (Appendix 2)
- The emergency department paediatric trauma imaging decision tool (Appendix 4).

This document is intended to ensure that the wellbeing and safety of the child is paramount.

References

1. The Royal College of Radiologists. *Standards of practice and guidance for trauma radiology in severely injured patients*. London: The Royal College of Radiologists, 2011.
2. TARNNet data 2013.
3. Mannix R, Nigrovic LE, Schutzman SA. Factors associated with the use of cervical spine computed tomography imaging in pediatric trauma patients. *Acad Emerg Med* 2011; **18**(9): 905–911.
4. Mannix R, Bourgeois FT, Schutzman SA, Bernstein A, Lee LK. Neuroimaging for pediatric head trauma: do patient and hospital characteristics influence who gets imaged? *Acad Emerg Med* 2010; **17**(7): 694–700.
5. Brenner D, Elliston C, Hall E, Berdon W. Estimated risks of radiation-induced fatal cancer from pediatric CT. *AJR Am J Roentgenol* 2001; **176**(2): 289–296.
6. Pearce MS, Salotti JA, Little MP *et al*. Radiation exposure from CT scans in childhood and subsequent risk of leukaemia and brain tumours: a retrospective cohort study. *Lancet* 2012; **380**(9840): 499–505.
7. Einstein AJ. Beyond the bombs: cancer risks of low dose medical radiation. *Lancet* 2012; **380**: 455–457.
8. Matthews J, Forsythe A, Brady Z *et al*. Cancer risk in 680 000 people exposed to CT scans in childhood or adolescence: data linkage of 11 million Australians. *BMJ* 2013; **346**: f2360.
9. Arthurs OJ, Bjørkum AA. Safety in pediatric imaging: an update. *Acta Radiol* 2013; **54**(9): 983–990.
10. Miglioretti DL, Johnson E, Williams A *et al*. The use of computed tomography in pediatrics and the associated radiation exposure and estimated cancer risk. *JAMA Pediatr* 2013; **167**(8): 700–707.
11. Strauss KJ, Goske MJ, Kaste SC *et al*. Image gently: Ten steps you can take to optimize image quality and lower CT dose for pediatric patients. *AJR Am J Roentgenol* 2010; **194**(4): 868–873.
12. Friese RS, Malekzadeh S, Shafi S, Gentilello LM, Starr A. Abdominal ultrasound is an unreliable modality for the detection of hemoperitoneum in patients with pelvic fracture. *J Trauma* 2007; **63**: 97–102.
13. Tayal VS, Nielsen A, Jones AE, Thomason MH, Kellam J, Norton HJ. Accuracy of trauma ultrasound in major pelvic injury. *J Trauma* 2006; **61**: 1453–1457.
14. Holmes JF, Gladman A, Chang CH. Performance of abdominal ultrasonography in pediatric blunt trauma patients: a meta-analysis. *J Pediatr Surg* 2007; **42**(9): 1588–1594.
15. National Institute for Health and Care Excellence. *CG 176 Head Injury: Triage, assessment, investigation and early management of head injury in children, young people and adults*. London: NICE, 2014.
16. Booth TN. Cervical spine evaluation in pediatric trauma. *AJR Am J Roentgenol* 2012; **198**(5): W417–W425.
17. Nigrovic LE, Rogers AJ, Adalgais KM *et al*; Pediatric Emergency Care Applied Research Network (PECARN) Cervical Spine Study Group. Utility of plain radiographs in detecting traumatic injuries of the cervical spine in children. *Pediatr Emerg Care* 2012; **28**(5): 426–432.

18. Thompson WL, Stiell IG, Clement CM, Brison RJ; Canadian C-Spine Rule Study Group. Association of injury mechanism with the risk of cervical spine fractures. *CJEM* 2009; **11**(1): 14–22.
19. Moore MA, Wallace EC, Westra SJ. Chest trauma in children: current imaging guidelines and techniques. *Radiol Clin North Am* 2011; **49**(5): 949–968.
20. Donnelly LF. Imaging issues in CT of blunt trauma to the chest and abdomen. *Pediatr Radiol* 2009; **39**(Suppl 3): 406–413.
21. Holmes JF, Brant WE, Bogren HG, London KL, Kuppermann N. Prevalence and importance of pneumothoraces visualized on abdominal computed tomographic scan in children with blunt trauma. *J Trauma* 2001; **50**(3): 516–520.
22. Brink M, Deunk J, Dekker HM *et al*. Added value of routine chest MDCT after blunt trauma: evaluation of additional findings and impact on patient management. *AJR Am J Roentgenol* 2008; **190**(6): 1591–1598.
23. Patel RP, Hernanz-Schulman M, Hilmes MA, Yu C, Ray J, Kan JH. Pediatric chest CT after trauma: impact on surgical and clinical management. *Pediatr Radiol* 2010; **40**(7): 1246–1253.
24. Renton J, Kincaid S, Ehrlich PF. Should helical CT scanning of the thoracic cavity replace the conventional chest x-ray as a primary assessment tool in pediatric trauma? An efficacy and cost analysis. *J Pediatr Surg* 2003; **38**(5): 793–797.
25. Moore HB, Faulk LW, Moore EE *et al*. Mechanism of injury alone is not justified as the sole indication for computed tomographic imaging in blunt pediatric trauma. *J Trauma Acute Care Surg* 2013; **75**(6): 995–1001.
26. Orwig D, DeCou J. Towards evidence-based emergency medicine: best BETs from the Manchester Royal Infirmary. BET 4: is physical exam and laboratory data sufficient to exclude intra-abdominal injury in the paediatric trauma patient? *Emerg Med J* 2012; **29**(3): 258–260.
27. Eppich WJ, Zonfrillo MR. Emergency department evaluation and management of blunt abdominal trauma in children. *Curr Opin Pediatr* 2007; **19**(3): 265–269.
28. Taylor GA. Imaging of pediatric blunt abdominal trauma: what have we learned in the past decade? *Radiology* 1995; **195**(3): 600–601.
29. Neish AS, Taylor GA, Lund DP, Atkinson CC. Effect of CT information on the diagnosis and management of acute abdominal injury in children. *Radiology* 1998; **206**(2): 327–331.
30. Sivit CJ. Abdominal trauma imaging: imaging choices and appropriateness. *Pediatr Radiol* 2009; **39**(Suppl 2): S158–S160.
31. Sivit CJ. Imaging children with abdominal trauma. *AJR Am J Roentgenol* 2009; **192**(5): 1179–1189.
32. Holmes JF, Sokolove PE, Brant WE *et al*. Identification of children with intra-abdominal injuries after blunt trauma. *Ann Emerg Med* 2002; **39**(5): 500–509.
33. Avarello JT, Cantor RM. Pediatric major trauma: an approach to evaluation and management. *Emerg Med Clin North Am* 2007; **25**(3): 803–836, x.
34. Rees MJ, Aickin R, Kolbe A, Teele RL. The screening pelvic radiograph in pediatric trauma. *Pediatr Radiol* 2001; **31**(7): 497–500.
35. Lagisetty J, Slovis T, Thomas R, Knazik S, Stankovic C. Are routine pelvic radiographs in major pediatric blunt trauma necessary? *Pediatr Radiol* 2012; **42**(7): 853–858.

36. Leonard M, Ibrahim M, Mckenna P, Boran S, McCormack D. Paediatric pelvic ring fractures and associated injuries. *Injury* 2011; **42**(10): 1027–1030.
37. Brady Z, Ramanauskas F, Cain TM, Johnston PN. Assessment of paediatric CT dose indicators for the purpose of optimisation. *Br J Radiol* 2012; **85**(1019): 1488–1498.
38. Brady SL, Moore BM, Yee BS, Kaufman RA. Pediatric CT: implementation of ASIR for substantial radiation dose reduction while maintaining pre-ASIR image noise. *Radiology* 2014; **270**(1): 223–231.

Appendix 1. General considerations and recommendations that will ensure patient safety is of the highest priority during imaging

All providers of clinical care should be working to improve the reliability of care so that patients and families can be confident that their safety will be paramount at all times. The safety of patients in complex situations challenges even the most organised departments.

The following check list is provided to support imaging departments and teams in their preparation for the management of children in the imaging department following injury. It is good practice to rehearse infrequent scenarios so that levels of confidence and competence in exceptional situations can be the highest possible. This can be part of a major trauma simulation or as part of a regular team review and verbal simulation with the imaging team only.

It is human nature to sometimes overlook important items when under the pressure of exceptional stress or limited time. Check lists and prompts reduce the risk of errors of omission (to forget) or commission (to do the wrong thing). Having trauma cards can enable high levels of reliability in even the most pressured of situations.

The following list is not exhaustive but is given to prompt the team to consider the patient and family experience as well as the importance of technique and imaging excellence:

1. Preparation for unexpected events
2. Environment
3. Communication with clinical teams
4. Communication with patient and family
5. Onward communication of results, events, and ensuring safe handover of care.
6. Reflection and feedback on learning.

Preparing for unexpected events. Sudden haemorrhage, deterioration in conscious level, cardiac arrest can all happen just before or during the imaging sequence. Regular review of the locations of emergency equipment and rehearsal of roles and responsibilities enables the fastest response. Ensuring that the team coming with the patient bring with them all necessary emergency equipment not available in the scanner suite is recommended. Thinking the unthinkable ensures preparedness.

Environmental factors are important considerations when children are critically ill. Ensuring appropriate precautions are taken to avoid the patient becoming cold is recommended. The value of age-specific comforters may or may not be appropriate depending on the severity of injury, but they can be considered. Reducing noise and commotion will help everyone focus on the patient.

Communications with the clinical team will be best undertaken using a structured communication tool such as situation, background, assessment and recommendation (SBAR). This may seem obvious, but in pressured situations ensuring communication is structured will avoid confusion or misunderstanding and ensure good team work (see Example 1).

Example 1.

Yes we can undertake the scan however:

(S) We have a patient on the scanner now and it will take five minutes to clear the room

(B) To bring the patient immediately into the scanner is, in our experience, safest

(A) We need ten minutes to clear and prepare, do you know the weight of the child so we can prepare the contrast?

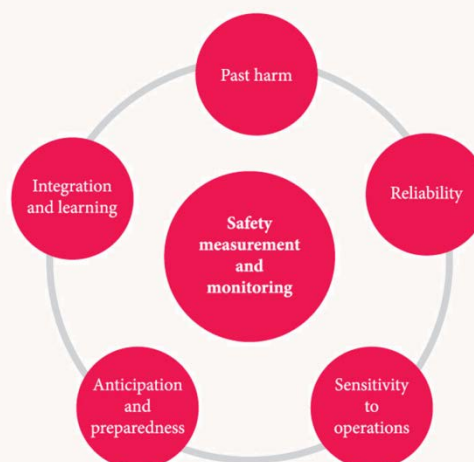(R) We recommend you arrive in ten minutes with all the necessary resuscitation equipment as we do not hold paediatric-sized equipment.

Communication with the patient and family should be sensitive and straight forward, avoiding complex terms that may confuse at the same time as being open. Ensuring the family know the order of events can turn a highly stressful situation into a less stressful one. Any questions about radiation dose should be answered, indicating the attention paid to dose minimisation and benefits and when and how the images will be reviewed. Due regard to radiation safety according to local protocols is necessary but so is the sensitive explanation of how the team are paying the very best attention to balancing risk and benefit. Sometimes rehearsal of a genuine script can help staff improve their management of this situation.

Onward communication of results should be clearly defined as part of the transfer of the patient from the imaging suite back to clinical area. This may not be easy to define exactly (reporting times may vary) but an indication of when the results will be available and how should be considered so as to create a consistent expectation. The NPSA/College guidance on communication of important findings^{i,ii} clearly applies in such situations and the department team should consider what their standard process will be. Any unexpected events observed in the imaging department should be included in the imaging record and in handover and clinical notes to ensure they are part of the clinical record. In such situations 'closed loop communications' is recommended; for example, the report will be available in ten minutes on the PACS, please ring us if it is not available after 15 minutes so we can find out why.

Reflection, feedback and learning are signs of a mature team with safety and 'mindfulness' at the forefront of their routine. Every event has the potential to teach someone something and unexpected events are critical learning situations that should be maximised through onward communication and the team considering 'how might we manage that better next time'. A lesson from military aviation is salient here, part of the debrief schedule is to ask, 'Thinking about what happened and what we know now, what should we have prepared for before we set off.'

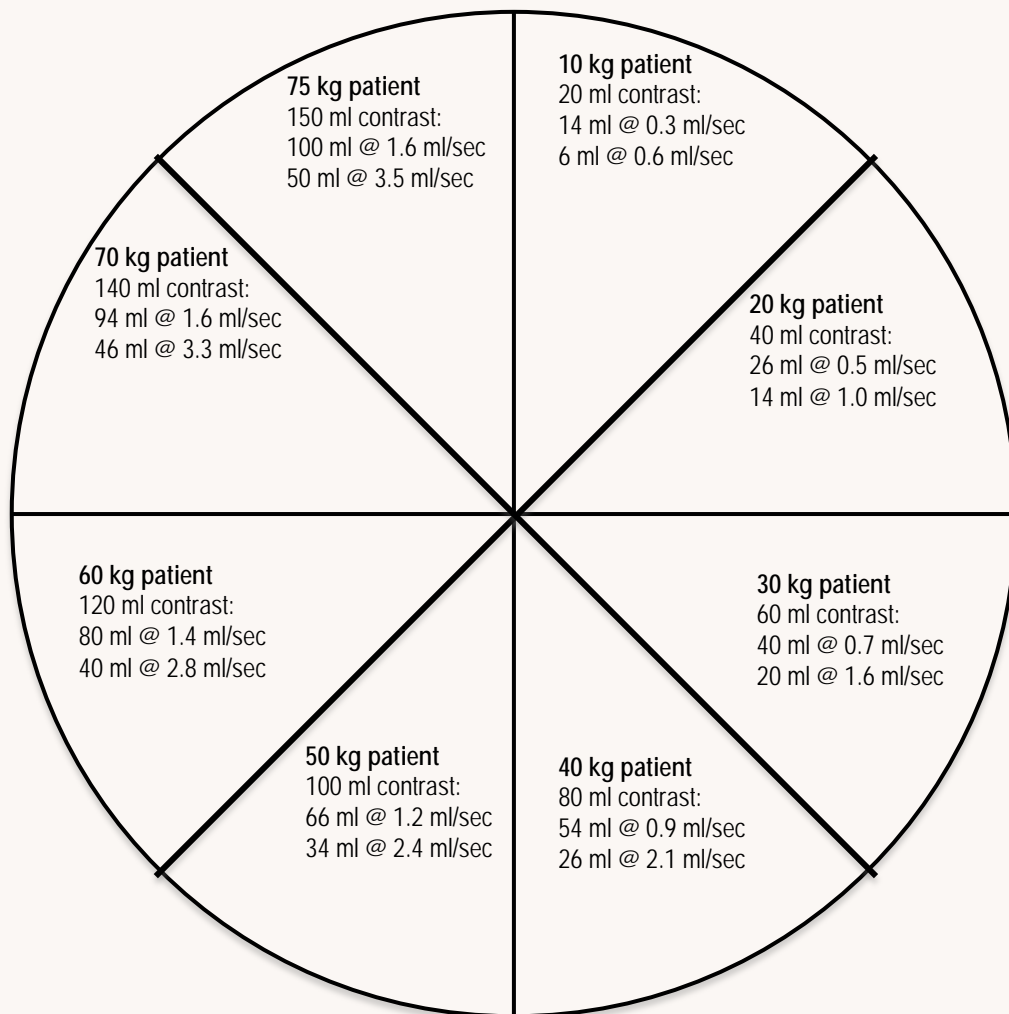
A framework with which to consider the measurement and monitoring of patient safety has five areas of attention as described below.ⁱⁱⁱ



- i. National Patient Safety Agency. *Safer practice notice 16. Early identification of failure to act on radiological imaging reports*. London: NPSA, 2007.
- ii. The Royal College of Radiologists. *Standards for the communication of critical, urgent and unexpected significant radiological findings*, Second edition. London: The Royal College of Radiologists, 2012.
- iii. Vincent C, Burnett S, Carthey J. *The measurement and monitoring of safety*. The Health Foundation, 2013. www.health.org.uk/publications/the-measurement-and-monitoring-of-safety

Appendix 2. Camp bastion contrast calculator

Scan protocol: 2/3 contrast volume injected at slow rate x, and 1/3 volume injected at approximately 2x.
Contrast rates are calculated for injection phase to last 70 secs. Scan initiated at 70 seconds.



Appendix 3. Acute primary assessment report for paediatric CT with major trauma

Patient name	
Patient number	
Date of scan	

To guide initial management only. A formal report will follow. The trauma team will be notified of any major alterations to this primary assessment

Primary assessment trauma plain films (for stable children)

Cervical spine

Normal	No CT C-spine indicated
Abnormal/clinical suspicion	CT C-spine required

Chest X-ray

Normal	No CT chest indicated Proceed to CT abdo/pelvis if needed
Abnormal/clinical suspicion	CT TAP required

CT scanning preliminary review

Airway:			
ET placement	N/A	Satisfactory	Unsatisfactory
Airway obstruction		Yes	No

Breathing:			
Contusion		Yes	No
Laceration		Yes	No
Pneumothorax		Yes	No
Chest drain placement	N/A	Satisfactory	Unsatisfactory

Circulation (bleeding):			
Pericardial effusion		Yes	No
Thoracic injury		Yes	No
Abdominal injury	retroperitoneal	Yes	No
	visceral	Yes	No
Pelvic injury		Yes	No
Soft tissue		Yes	No

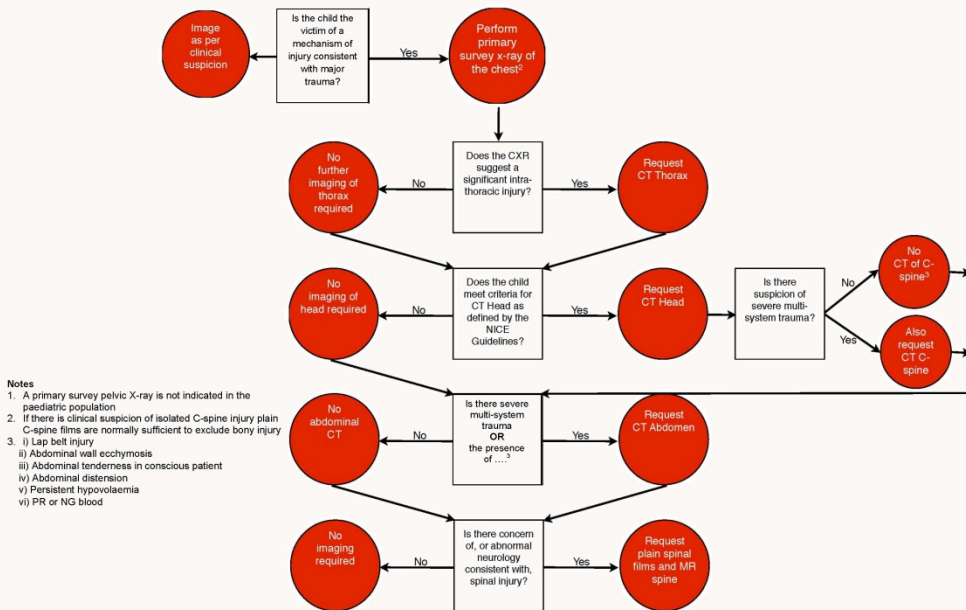
Disability:		
Intracranial bleed/oedema	Yes	No
Major spinal injury (cord compromise)	Yes	No

Comments:	
Name of radiologist	
Time	

Appendix 4. Emergency department paediatric major trauma imaging decision tool

Developed by Dr Tony Kehoe, ED Consultant, Derriford Emergency Department

Emergency department paediatric major trauma imaging decision tool



Citation details

The Royal College of Radiologists.
Paediatric trauma protocols. London: The
Royal College of Radiologists, 2014.

Ref No. BFCR(14)8
© The Royal College of Radiologists, August
2014.

For permission to reproduce any of the content
contained herein, please email:
permissions@rcr.ac.uk

This material has been produced by The Royal
College of Radiologists (RCR) for use internally
within the specialties of clinical oncology and clinical
radiology in the United Kingdom. It is provided for
use by appropriately qualified professionals, and the
making of any decision regarding the applicability
and suitability of the material in any particular
circumstance is subject to the user's professional
judgement.

While every reasonable care has been taken to
ensure the accuracy of the material, RCR cannot
accept any responsibility for any action taken, or not
taken, on the basis of it. As publisher, RCR shall not
be liable to any person for any loss or damage,
which may arise from the use of any of the material.
The RCR does not exclude or limit liability for death
or personal injury to the extent only that the same
arises as a result of the negligence of RCR, its
employees, Officers, members and Fellows, or any
other person contributing to the formulation of the
material.

The Royal College of Radiologists
63 Lincoln's Inn Fields, London WC2A 3JW
Tel: +44 (0)20 7405 1282
Email: enquiries@rcr.ac.uk **www.rcr.ac.uk**



A Charity registered with the Charity Commission No. 211540