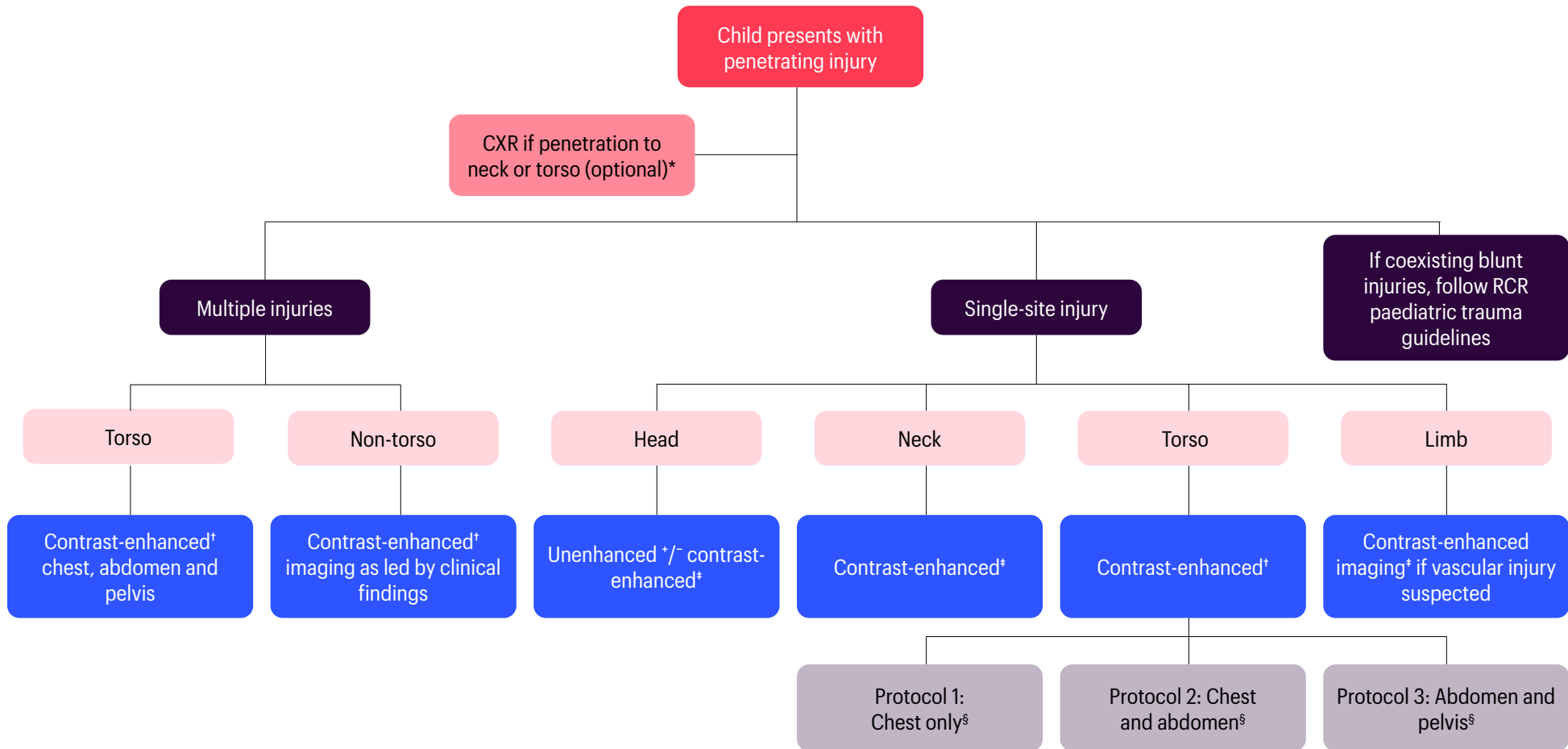


A3

Suggested algorithm for the imaging of penetrating trauma in paediatric patients



* The need for CXR is a clinician-led decision, based on factors such as history and examination findings, patient stability, need for intervention, availability of cross-sectional imaging, etc

† Bastion or modified Bastion protocol is considered the standard for contrast administration, although the choice between the two protocols would be based on local practice

‡ Consider CT angiogram in place of Bastion or modified Bastion protocol if arterial injury is suspected

§ A wider CT coverage rather than a single body part should be considered if the entry wound occurs at the junction of two body parts or if there was a possibility of a wound depth or trajectory crossing between two body parts