NOVEMBER 2026

Clinical Radiology

Imaging acute abdominal and pelvic presentations in pregnancy Consensus guidelines from BSUR, BSGAR and the RCR

The Royal College of Radiologists

BSUR

BSGAR



Contents

Introduction 3
Authors and contributors 4
Methodology 5
Guidelines and recommendations 6

1 Governing concepts 9
Decision-making and clinical involvement 9
Assessment of the fetus 11

2 Imaging use in specific clinical scenarios 12
Life-threatening emergency, clinically unstable patient 12
Suspected acute obstetric emergency 12
Suspected acute appendicitis 13
Suspected acute small or large bowel pathology (excluding appendicitis) 13
Suspected other non-obstetric acute abdominal or pelvic pathology 14

3 How to deliver a service 15
Ultrasound 15
MRI 16
CT 18
Plain radiography 19
Service provision and training 20

4 Discussion 21
5 Conclusion 22
6 Acknowledgements 23

Appendices
Appendix 1: Literature 24
Appendix 2a: Example patient information leaflet – MRI 25
Appendix 2b: Example patient information leaflet – CT 27
Appendix 2c: Example patient consent form for CT imaging in pregnancy 30
Appendix 3a: Suggested MRI protocol for AAPP in pregnancy 32
Appendix 3b: Practical considerations for CT in AAPP in pregnancy 34

References 35

Introduction

Acute abdominal and pelvic symptoms are common during pregnancy. Most are physiological or self-limiting in nature – such as uterine contractions, round ligament pain, compression from the gravid uterus or hormonal effects on the gastrointestinal tract. However, identifying acute abdominal and pelvic presentations (AAPP) in pregnancy that may require medical or surgical intervention presents significant diagnostic challenges. Clinical and radiological evaluation can be complicated by pregnancy-related physiological changes, displacement of abdominal and pelvic organs by the gravid uterus, and altered blood parameters like white cell count.[1,2]

Timely and accurate diagnosis of more serious conditions is essential to safeguard the health of both the pregnant patient and the fetus. While imaging is central to evaluating many of these conditions, it also carries potential risks. Concerns about radiation exposure – shared by both patients and clinicians – can complicate decision-making. However, in many acute scenarios, the actual risks associated with imaging are often lower than perceived and are outweighed by the benefits of timely diagnosis and intervention. While all imaging should adhere to ALARA (as low as reasonably achievable) principles, and computed tomography (CT) should be reserved as a last resort in most cases, surgical intervention is required in approximately 0.5% to 2% of these cases; imaging therefore plays a critical role in identifying those who need intervention, offering a safer and less invasive alternative to diagnostic laparoscopy.[3]

Within the current UK/NHS setting, access to imaging is not always consistent, and the level of interpretative expertise, particularly outside of normal working hours, can vary. A national survey conducted by the British Society of Urogenital Radiology (BSUR) and the British Society of Gastrointestinal Radiology (BSGAR) highlighted variation in practice, knowledge and confidence among UK radiologists when managing these complex cases.[4]

To address these issues, BSUR, BSGAR and The Royal College of Radiologists (RCR) have collaborated to produce practical, evidence-based guidelines for use in radiology departments nationwide. Developed by a panel of UK-based NHS radiologists, these guidelines aim to provide a clear, standardised approach to support radiologists and clinical teams across the UK in imaging AAPP in pregnancy effectively.

Authors and contributors

In 2023 BSUR, BSGAR and the RCR committed to developing these consensus guidelines. BSUR and BSGAR members were invited by email to participate in a panel and were appointed to ensure broad geographical representation across the UK, with input of consultants who work in varied hospital settings. The panel comprised 17 radiologists: 2 chairs (appointed by BSUR and BSGAR), 1 research fellow and 14 panel members.

	Geographic place of work	Affiliation
Panel chairs		
Faye Cuthbert	Brighton, England	BSUR
Rebecca Wiles	Liverpool, England	BSGAR/BSUR
Research fellow		
Rachel Gravell	Leeds, England	BSGAR
Panel members		
Ian Zealley	Dundee, Scotland	BSGAR
James Stephenson	London, England	BSGAR
Vikas Shah	Leicester, England	BSGAR
Katherine Moore	Newport, Wales	BSUR
Catalin Ivan	Buckinghamshire, England	BSGAR
Damian Tolan	Leeds, England	BSGAR
Samantha Fossey	West Sussex, England	BSUR
Joanna McNeil	Glasgow, Scotland	BSUR
Nishat Bharwani	London, England	BSUR
Beth Hankinson	Liverpool, England	BSUR
Michael Pyper	Belfast, Northern Ireland	BSUR
Claire Keaney	Cornwall, England	BSUR
Brooke Lawson	Tayside, Scotland	BSUR
John Spillane	Glamorgan, Wales	BSGAR
Radiographer contributors		
Stephanie Hanna	Liverpool, England	CT radiographer
Leonardos Papadopoullos	Liverpool, England	MRI radiographer
Sophie Freeman	Liverpool, England	MRI radiographer

Methodology

The guidelines development process followed the principles outlined in the European Society of Gastrointestinal Radiology (ESGAR) *Guidelines for the development of consensus guidelines*, using a modified Delphi methodology, and was broadly informed by the AGREE II instrument.[5,6,7,8]

Following selection of the panel and chairs, the scope and aims of the guidelines were defined at a face-to-face meeting. The chairs then developed an initial detailed questionnaire covering all proposed items for inclusion in the consensus statement. This draft was circulated to the panel for feedback and subsequently refined based on their responses.

A comprehensive literature search was conducted to identify relevant studies, with the search strategy outlined in Appendix 1. Abstracts were screened, and a curated list of studies was shared with the group. The literature review focused on imaging safety in suspected AAPP during pregnancy and on strategies for achieving accurate, timely diagnosis within current UK/NHS resources.

Approved questionnaires were converted into individual consensus statements and distributed to the panel along with the supporting literature. Panel members rated their agreement using a five-point Likert scale (1=strongly disagree, 5=strongly agree). Statements that achieved ≥80% agreement (ratings of 4 or 5) were accepted, with corresponding levels of evidence cited. For statements that did not reach consensus, revisions and discussions were undertaken, leading to further rounds of voting. In total, three Delphi rounds were required. Suggested magnetic resonance imaging (MRI) protocols for AAPP in pregnancy (Appendix 3a) were reviewed by expert MRI radiographers. 'Practical considerations for CT in AAPP in pregnancy' (Appendix 3b) was written by an expert CT radiographer.

The manuscript was then prepared by the coordinating chairs and circulated to the group, including example patient information leaflets (PILs), consent forms and scan protocols. The final draft version was approved by the RCR Professional Practice Board and submitted for public consultation.

Specific patient group feedback was sought and received from the Society of Radiographers Patient Advisory Group, and changes to the guidelines and appendices were made accordingly.

The RCR's professional networks, as well as the specific groups listed below, were also directly contacted to make them aware of the consultation period:

- Society of Radiographers
- British Medical Ultrasound Society
- Royal College of Emergency Medicine
- Royal College of Obstetrics and Gynaecology
- Royal College of Surgeons surgical specialty associations (including Association of Surgeons of Great Britain and Ireland, British Association of Urological Surgeons, British Society of Gastroenterology).

Following the public consultation and feedback, the final manuscript was compiled.

Guidelines and recommendations

A summary of the recommendations is described in the algorithm (Figure 1). Each point in the algorithm is discussed separately below. Grades of evidence as per the Oxford Centre for Evidence-Based Medicine (OCEMB) agreement level of the group (in %) and strength of recommendation are included in brackets after each statement.[9,10]

The guidelines are divided into three sections:

1. Governing concepts
2. Imaging use in specific clinical scenarios
3. How to deliver a service.

Imaging acute abdominal and pelvic presentations (AAPP) in pregnancy

In all cases, the decision to undertake imaging must be weighed against non-imaging options (including a period of observation, if appropriate).

All recommendations assume that imaging has been deemed necessary following appropriate consideration and involvement of clinical and radiological teams.

'Availability/appropriateness' of imaging includes not just access to equipment but also an appropriately experienced person to interpret and report within a suitable time frame. However, the ready availability of CT does not, in itself, justify its use in pregnant patients without thorough assessment of all alternative options.

For all imaging modalities, ALARA principles should be adhered to.

Figure 1. Summary of recommendations

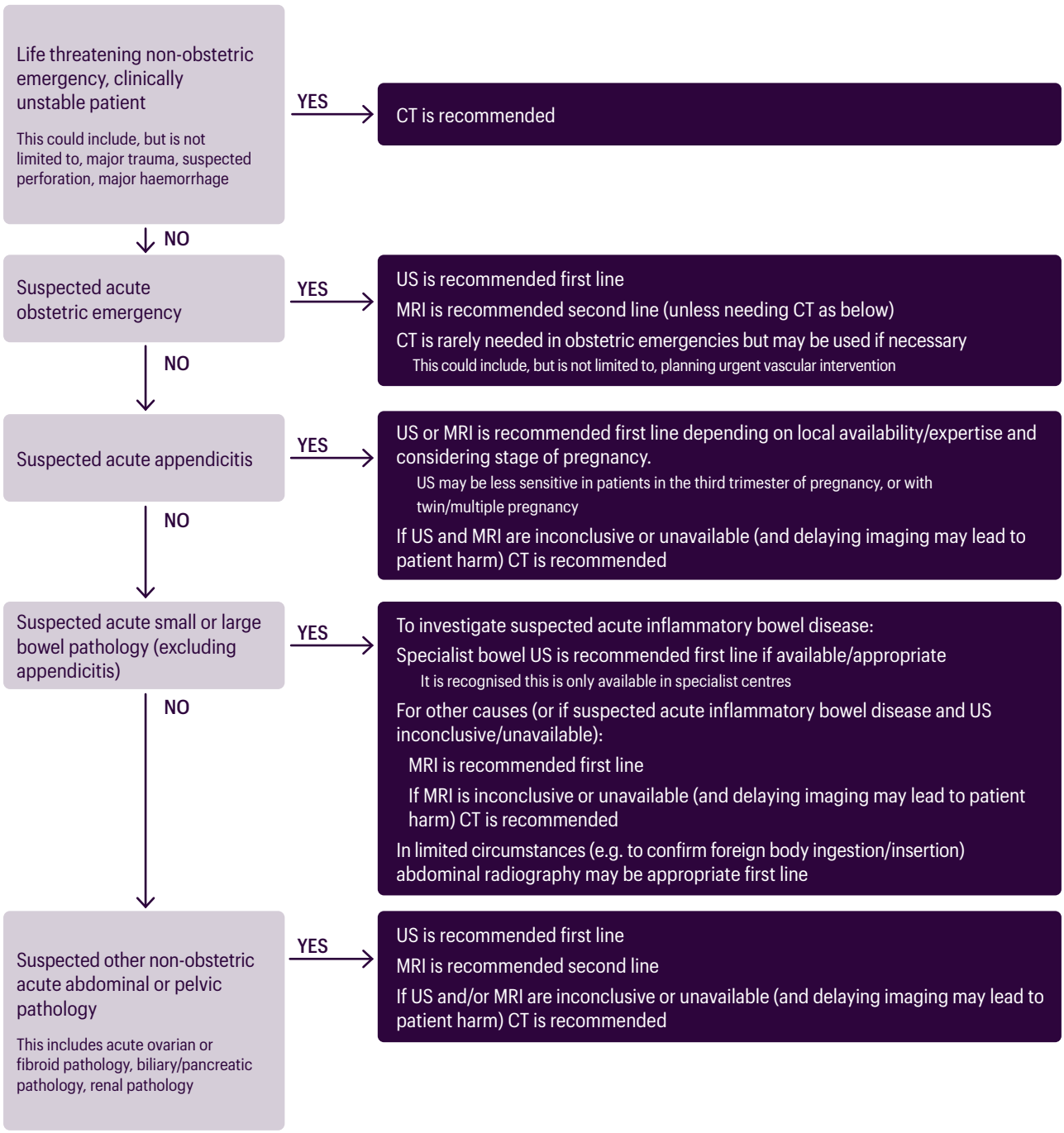

Guidance notes

Ultrasound

- The patient should be advised that ultrasound causes no known risks to the fetus.
- Specific documented consent (beyond that obtained for non-pregnant patients) is not required.
- The use of a Patient Information Leaflet (PIL) is not required.

MRI

- The patient should be advised that MRI causes no known risk to the fetus.
- Specific documented consent (beyond that obtained for non-pregnant patients) is not required.
- The use of a PIL is recommended.
- For AAPP in pregnancy, MRI can be used in any stage of pregnancy and is preferable to CT.
- In the non-acute setting, due to theoretical risks, MRI should/could be delayed until the second trimester, but this is not appropriate to AAPP in pregnancy.
- Radiology departments should have an MRI protocol for investigating AAPP in pregnancy. The protocol may be tailored to the clinical question.
- It is recommended that, if possible, a radiologist supervise the MRI scan (either remotely or on-site) to tailor the study, provided it does not cause delay that may lead to patient harm.
- Intravenous gadolinium-based contrast should be avoided.
- Anti-spasmodic agents (eg hyoscine butylbromide (buscopan)) should be avoided.

CT

- The risks and benefits of the imaging investigation should be discussed with the patient and/or their advocate (if present and the patient is too unwell to have the discussion).
- This would typically be by an appropriately senior member of the clinical team following input from a radiologist.
- The designated member of the clinical team should obtain consent (if possible) and document it in the patient record. If the patient is unable to consent (eg because they are too unwell), the team can determine that the scan is in the patient's best interests, and it should proceed without delay.
- The use of a PIL is recommended.
- Radiology departments should have a CT protocol for investigating AAPP in pregnancy. The protocol may be tailored to the clinical question.
- Intravenous contrast can be administered as it would be for the same clinical indication in a patient who is not pregnant.
- If intravenous contrast is required, the nominated member of the team should advise the patient that there is a theoretical risk of hypothyroidism and a heel prick test is advised at birth (and that this is performed as part of routine neonatal screening in the UK).
- Abdominal shielding should be avoided.

01 Governing concepts

Decision-making and clinical involvement

Imaging in pregnancy involves balancing maternal and fetal considerations, recognising that maternal health is essential to fetal wellbeing. Decisions should be based on clinical urgency, the potential risks of imaging and the diagnostic value of available modalities. In the current UK/NHS setting, these decisions are also shaped by rising demand, limited resources and the need for multidisciplinary input. The following principles form the basis for safe, effective and patient-focused imaging in pregnancy.

1. Imaging should be available for the evaluation of patients presenting with AAPP in pregnancy. (Agreement: 100%, Evidence grade: D, Strength of recommendation: strong)
2. Non-ionising imaging modalities (eg ultrasound, MRI) should be prioritised over ionising radiation modalities (eg CT, X-ray) in pregnant patients at all stages of pregnancy if appropriate to the clinical scenario. (Agreement: 100%, Evidence grade: A, Strength of recommendation: strong)
3. For all imaging modalities, the ALARA principles should be adhered to. This should not be at the expense of obtaining adequate diagnostic information. (Agreement: 100%, Evidence grade: B, Strength of recommendation: strong)
4. The decision to use imaging should involve a risk–benefit analysis, considering the stage of pregnancy and clinical scenario. (Agreement: 100%, Evidence grade: D, Strength of recommendation: strong)
5. 'Availability/appropriateness' of imaging includes not just access to equipment but also an appropriately experienced person* to interpret and report within a suitable time frame. (Agreement: 100%, Evidence grade: B, Strength of recommendation: strong)

   *Depending on the imaging modality, this may include, but is not limited to, a radiologist, sonographer or obstetrician.
6. A multidisciplinary approach involving obstetricians, radiologists and surgeons/physicians is recommended in imaging AAPP in pregnancy. The seniority of team members will depend on the clinical scenario, but will usually involve consultant to consultant referral, especially if involving ionising radiation. (Agreement: 100%, Evidence grade: B, Strength of recommendation: strong)

01 Governing concepts

Imaging plays a crucial role in assessing most patients with acute abdominal and pelvic presentations. This remains true in pregnancy, but there is the added consideration of how different imaging modalities may affect the fetus.[2,11,12,13,14,15]

The fetus is particularly sensitive to ionising radiation, especially during early gestation. While the radiation doses used in a one-off diagnostic imaging study are below the thresholds associated with deterministic effects such as miscarriage, growth restriction or congenital anomalies, there remains a theoretical, dose-dependent stochastic risk of childhood cancer.[16,17] The exact risk for each individual varies with multiple factors and as such can only be estimated. According to the International Commission on Radiological Protection (ICRP), in utero exposure to 10 mGy is associated with a risk of death from childhood cancer of approximately 1 in 1,700 exposed individuals. This needs to be interpreted in line with background risk, which is approximately 1 in 500.[18]

Given this small but uncertain risk, non-ionising imaging modalities (ultrasound and MRI) are preferred over ionising techniques (primarily CT and plain radiography).[19,20,21,22] Nonetheless, ionising studies may be justified when the diagnostic benefit outweighs the potential fetal risk. The ALARA principles should always be observed, and current IR(ME)R regulations (at the time of writing, latest amendment in 2024) must also be followed.[23,24,25]

Imaging decisions require careful consideration of the suspected diagnosis, the likelihood that imaging will alter management, the diagnostic value and safety of available modalities, alternative options (including proceeding straight to surgery or opting for a 'watchful waiting' approach) and the patient's informed wishes. In pregnancy, these considerations are even more critical, and senior clinical and radiological input is strongly recommended in such cases.[26,27] Where possible, quantifiable risks of available options should be given to the patient to enable informed decision-making.

Concerning MRI, where scanners with field strengths of 1.5 Tesla (1.5 T) and 3 Tesla (3 T) or higher are available, there is no evidence that higher field strength is harmful to the pregnant person or fetus.[28] However, the use of 1.5 T should be preferred in keeping with ALARA principles. When clinically indicated and available, MRI at 3 T remains preferable to imaging techniques that involve ionising radiation.

The 2025 BSUR–BSGAR survey demonstrated significant variation in imaging practice across UK centres.[4] In particular, the availability of different imaging modalities and the expertise required to interpret studies varied both geographically and according to the time of day or week. The panel therefore emphasises the critical importance of 'availability' when planning imaging for AAPP in pregnancy. Availability should be understood to encompass not only physical access to imaging equipment but also access to appropriately trained personnel. This includes qualified operators (typically radiographers for CT or MRI, or sonographers or radiologists for ultrasound) as well as a suitably experienced person to interpret the results and produce an accurate report (usually radiologists for CT or MRI, and radiologists or sonographers for ultrasound). Ensuring both technical and interpretive expertise is essential to ensure timely and accurate imaging for this group of patients.

01
Governing concepts

Assessment of the fetus

7. If the radiologist reporting the study does not have expertise in obstetric/placental imaging, a comment* can be made in the report that the study is to assess for non-obstetric pathology, and the fetus and placenta have not been assessed. (Agreement: 100%, Evidence grade: D, Strength of recommendation: strong)

   *For example: 'The study is conducted to assess non-obstetric pathology. The fetus and placenta cannot be reliably evaluated as part of this examination. Correlation with formal obstetric ultrasound is advised if clinically appropriate.'

The BSUR–BSGAR survey on current clinical practice[4] found considerable variation in how the fetus and placenta were assessed in scans performed for AAPP in pregnancy, reflecting the limited familiarity most radiologists have with fetal imaging.[4,29] In the survey, 42% of radiologists stated in their report that the fetus or placenta was not assessed, while 12% made no comment.

The panel recommends that when a pregnant patient requires imaging for AAPP, the reporting radiologist or sonographer should not be constrained by lack of expertise in fetal or placental assessment.[11,30] In urgent scenarios, maternal wellbeing is the primary consideration, and the reporter should provide a report addressing the clinical question relating to maternal health or survival. It is acknowledged that, while existing RCR guidance emphasises that the entire imaging field should be reviewed systematically, and any clinically relevant findings reported regardless of the indication, this requires careful consideration in the case of pregnancy.[30] Assessment of the fetus and placenta on non-obstetric imaging is inherently limited, as accurate evaluation requires dedicated specialist sequence planning and expertise, including acquisition in planes tailored to the fetus/placenta. In addition, fetal and placental abnormalities are routinely assessed through standard antenatal screening pathways; therefore, incidental appearances on non-targeted imaging should be interpreted with caution. If additional fetal assessment is required, this would usually be performed with ultrasound, or in selected cases by referral for specialist centre fetal MRI, though the latter is rarely indicated in the acute setting.

02 Imaging use in specific clinical scenarios

Life-threatening emergency, clinically unstable patient

1. In suspected acute life-threatening non-obstetric pathology requiring imaging,* choice of imaging is determined by availability and clinical urgency. The welfare of the pregnant patient should be the primary consideration, and CT is typically the most appropriate imaging modality in these circumstances. (Agreement: 100%, Evidence grade: B, Strength of recommendation: strong)

   *This could include, but is not limited to, major trauma, suspected gastrointestinal tract perforation, major haemorrhage.

Trauma is the leading non-obstetric cause of death in pregnant women.[31] When imaging is required for suspected acute, life-threatening emergencies – including major trauma – the panel recommends CT as the primary imaging method, since the risk to the pregnant patient from missed serious pathology likely far exceeds the potential radiation risk to the fetus.[32,33,34] This approach aligns with guidelines from both the European Trauma Course and Advanced Trauma Life Support.[31,35]

Suspected acute obstetric emergency

1. Decision to request imaging will be led by the obstetric team. (Agreement: 86%, Evidence grade: D, Strength of recommendation: strong)
2. When imaging is required, ultrasound is recommended as the firstline investigation. (Agreement: 93%, Evidence grade: B, Strength of recommendation: strong)
3. In limited scenarios MRI should be considered as a secondline investigation. (Agreement: 93%, Evidence grade: B, Strength of recommendation: strong)
4. CT is rarely needed in obstetric emergencies but may be used if necessary.* (Agreement: 100%, Evidence grade: B, Strength of recommendation: strong)

   *This could include, but is not limited to, planning urgent vascular intervention.

Some causes of AAPP in pregnancy are directly related to the gravid uterus. These include ectopic pregnancy, placental abruption and uterine rupture. Such conditions are typically suspected and managed by the obstetric team, with ultrasound being the recommended firstline imaging modality.[36] If ultrasound does not provide sufficient information, MRI is recommended as the next step.[37] CT is rarely required, but in emergency situations – such as suspected acute bleeding – it may be preferable to proceeding directly to emergency surgery.[38,39] As these situations are expected to be rare, the panel recommends discussion between the most senior members of the team, as outlined in Section 1.

02
Clinical scenarios

Suspected acute appendicitis

1. If imaging is required, ultrasound or MRI is recommended as the firstline investigation if available/appropriate. Choice of imaging with ultrasound or MRI depends on local availability/expertise and stage of pregnancy.* (Agreement: 100%, Evidence grade: B, Strength of recommendation: strong)

   *Ultrasound may be less sensitive in patients in the third trimester of pregnancy, or with twin/multiple pregnancy.

2. If ultrasound and MRI are inconclusive/unavailable (and delaying imaging may lead to patient harm), CT may be considered if appropriate to the clinical scenario. (Agreement: 100%, Evidence grade: B, Strength of recommendation: strong)

In pregnancy, the appendix is often displaced or compressed by the gravid uterus, making it harder to visualise on ultrasound. Reported accuracy varies widely due to operator dependence and gestational age. Two recent meta-analyses report sensitivities of 56% and 77.6%, and specificities of 88% and 75.3%.[37,38] Sensitivity also declines with advancing pregnancy – from 69% in the first trimester to 51% in the third.[40,41]

MRI offers higher accuracy, with reported sensitivity and specificity of 92% and 98%, though its use is limited by availability, timing and reporting expertise.[42]

While CT data in pregnant patients are limited, as it is rarely indicated or performed, studies in non-pregnant populations show high accuracy – 97% sensitivity and 96% specificity.[43]

The panel recommends using ultrasound or MRI based on local access and expertise. While ultrasound is typically firstline, upfront MRI may be preferred later in pregnancy, if available, to expedite management. Given CT's wide availability and diagnostic performance, its use is occasionally justified as a last resort when it is clinically required, for example when non-ionising techniques are not available or inconclusive, and if the patient is considered too unwell to undergo a period of observation.

Suspected acute small or large bowel pathology (excluding appendicitis)

1. To investigate acute inflammatory bowel disease, specialist bowel ultrasound* is recommended if available/appropriate. (Agreement: 93%, Evidence grade: C, Strength of recommendation: strong)

   *It is recognised this may only be available in specialist centres with local expertise.

2. For other causes (or if suspected acute inflammatory bowel disease and ultrasound is inconclusive/unavailable) MRI is recommended if available/appropriate. (Agreement: 86%, Evidence grade: C, Strength of recommendation: strong)

3. If MRI is inconclusive/unavailable (and delaying imaging may lead to patient harm), CT may be considered if appropriate to the clinical scenario. (Agreement: 100%, Evidence grade: B, Strength of recommendation: strong)

4. In limited circumstances (eg to confirm foreign body ingestion/insertion) abdominal radiography may be appropriate as a firstline investigation. (Agreement: 86%, Evidence grade: D, Strength of recommendation: strong)

02
Clinical scenarios

In non-pregnant patients, suspected acute bowel pathology is usually investigated with ionising radiation, most commonly abdominal radiography or CT. Specialist bowel ultrasound has variable availability across the UK, but in centres with expertise it has demonstrated high sensitivity (92%) for detecting small bowel Crohn's disease.[44] For selected indications (such as suspected inflammatory bowel disease) in specialist centres, ultrasound may be a suitable firstline test for pregnant patients presenting acutely.

While not commonly used in non-pregnant patients, MRI can be used to diagnose small bowel obstruction.[45] In patients presenting with suspected bowel obstruction or other bowel pathology, MRI is recommended firstline to avoid ionising radiation. If MRI is unavailable, or local expertise is limited, and delaying imaging may lead to patient harm, CT should be performed when imaging is required.

The panel does not recommend routine use of abdominal radiographs, as they expose the patient to ionising radiation but are unlikely to provide sufficient diagnostic information to guide management.[46] Exceptions include limited scenarios such as confirming or excluding a radiopaque foreign body that may cause harm.[47]

Suspected other non-obstetric acute abdominal or pelvic pathology

Examples are acute ovarian or fibroid pathology, biliary/pancreatic pathology, renal pathology.

1. Ultrasound is recommended as the firstline investigation if available/appropriate. (Agreement: 93%, Evidence grade: D, Strength of recommendation: strong)
2. If ultrasound is inconclusive/unavailable/inappropriate, MRI is recommended if available/appropriate. (Agreement: 100%, Evidence grade: C, Strength of recommendation: strong)
3. If MRI is inconclusive/unavailable (and delaying imaging may lead to patient harm), CT may be considered if appropriate to the clinical scenario. (Agreement: 100%, Evidence grade: B, Strength of recommendation: strong)

Outside of the specific scenarios described above, ultrasound is generally recommended firstline in AAPP in pregnancy if available/appropriate, with MRI or CT secondline depending on availability.[48,49]

03 How to deliver a service

Ultrasound

1. The patient should be advised that ultrasound causes no known risk to the fetus. (Agreement: 100%, Evidence grade: A, Strength of recommendation: strong)
2. Specific documented consent (beyond that obtained for non-pregnant patients) is not required. (Agreement: 100%, Evidence grade: D, Strength of recommendation: strong)
3. The use of a PIL is not required. (Agreement: 93%, Evidence grade: D, Strength of recommendation: strong)

Diagnostic ultrasound is considered safe in pregnancy, with no evidence of adverse maternal, fetal, perinatal or childhood outcomes.[2,11,13,50] Theoretical risks from tissue heating and mechanical effects have not been demonstrated in human studies. Potential temperature elevation is minimal with B-mode imaging but higher with colour and spectral Doppler; therefore, the thermal index and mechanical index should be kept ALARA, with obstetric presets ensuring parameters remain within safe limits.[50] As most patients are already familiar with the safety of ultrasound in pregnancy, an extended discussion of these technical considerations is not necessary. The panel does not recommend a separate consent process or PIL solely due to pregnancy.[2,19]

03
How to deliver a service

MRI

1. The patient should be advised that MRI causes no known risk to the fetus. (Agreement: 100%, Evidence grade: A, Strength of recommendation: strong)
2. Specific documented consent (beyond that obtained for non-pregnant patients) is not required. (Agreement: 100%, Evidence grade: D, Strength of recommendation: strong)
3. The use of a PIL is recommended.* (Agreement: 71%, Evidence grade: B, Strength of recommendation: weak)

   *An example of a PIL is given in Appendix 2a.
4. In AAPP in pregnancy, MRI can be used in any stage of pregnancy,* and is preferable to CT. (Agreement: 86%, Evidence grade: C, Strength of recommendation: strong)

   * In the non-acute setting, due to theoretical risks, MRI should/could be delayed until the second trimester, but this is not appropriate to AAPP in pregnancy.
5. Radiology departments should have an MRI protocol* for investigating AAPP in pregnancy. The protocol may be tailored to the clinical question. (Agreement: 100%, Evidence grade: D, Strength of recommendation: strong)

   * An example protocol is given in Appendix 3a.
6. It is recommended that, if possible, a radiologist supervise the MRI scan (either remotely or on-site) to tailor the study, provided it does not cause delay that may lead to patient harm. (Agreement: 100%, Evidence grade: D, Strength of recommendation: strong)

MRI does not use ionising radiation and is considered safe in pregnancy, as there is no conclusive evidence of fetal harm.[2,19,48] Although theoretical risks such as fetal hyperthermia and inner ear damage have been proposed, these are mitigated by modern scanner techniques, including reduced specific absorption rate (SAR) and optimised scan duration.[2,11,28] As organogenesis occurs in the first trimester, some guidelines suggest MRI should be deferred until after this period where possible.[19] However, the panel recommends that this is not usually practical in the acute setting and MRI can still be used safely in the first trimester for AAPP in pregnancy when clinically indicated.[14,20,51,52]

Patients should be informed that MRI is not known to cause harm in pregnancy and is safer than imaging that uses ionising radiation. Specific documented consent for MRI in pregnancy is not required, in line with standard UK/NHS practice for clinically indicated imaging performed within accepted safety parameters. However, the panel recommends that clinical teams consider providing a PIL to support communication and alleviate concerns.[53] This is not a 'strong' recommendation, as many panel members felt it was unnecessary and could inadvertently cause anxiety in patients who are already being reassured that MRI is safe during pregnancy. An example PIL can be found in Appendix 2a.

03
How to deliver a service

Because the gravid uterus can compress the inferior vena cava, patients in later pregnancy may be positioned in the lateral decubitus position for MRI, with guidance from a senior radiographer to ensure comfort and safety.

Responders to the BSUR–BSGAR survey[4] reported that out-of-hours MRI may be handled by radiologists in training or teleradiology providers (see 'Service provision and training' in Section 3) who may be unfamiliar with local protocols.[4] To reduce delays and ensure consistent practice, the panel recommends that all departments implement a default protocol for MRI in suspected AAPP in pregnancy. A suggested protocol is provided (see Appendix 3a), designed to be concise and adaptable. The panel recommends structuring sequences so that the examination can be terminated early if the clinical question is answered (eg identification of an inflamed appendix on initial sequences) if a supervising radiologist is available. This is in line with ALARA principles.[48,54] While the panel recognises that (direct or remote) supervision may not be practical in all UK/NHS settings, particularly out of hours, this is presented as an aspirational standard to reduce scan time and to ensure sufficient diagnostic information is obtained.

7. Intravenous gadolinium-based contrast should be avoided. (Agreement: 100%, Evidence grade: A, Strength of recommendation: strong)
8. Anti-spasmodic agents (eg hyoscine butylbromide (buscopan)) should be avoided. (Agreement: 86%, Evidence grade: D, Strength of recommendation: strong)

The administration of intravenous gadolinium during pregnancy has been associated with a small increase in the risk of rheumatological, inflammatory or dermatological conditions, as well as stillbirth and neonatal death.[2,48,55] Therefore, the panel recommends against the use of intravenous gadolinium unless the benefits outweigh the risks – this is rarely, if ever the case in the investigation of AAPP in pregnancy.

The panel does not recommend the use of hyoscine butylbromide (buscopan) (during MRI in pregnancy.[2,56] Although widely used in general MRI protocols, its safety in pregnancy is not well established. The summary of product characteristics notes that reproductive safety data from animal studies are inadequate, and its use in pregnancy is therefore not advised as a precautionary measure.[57] Additionally, the panel notes that later in pregnancy hyoscine butylbromide (buscopan) may not provide as much benefit due to reduced bowel motility and limited displacement of bowel loops by the gravid uterus.[1]

03
How to deliver a service

CT

1. The risks and benefits of the imaging investigation should be discussed* with the patient and/or their advocate (if present and the patient is too unwell to have the discussion). (Agreement: 100%, Evidence grade: D, Strength of recommendation: strong)

   *This would typically be by an appropriately senior member of the clinical team following input from a radiologist.

2. The designated member of the clinical team should obtain consent (if possible) and document it in the patient record. If the patient is unable to consent (eg because they are too unwell), the team can determine that the scan is in the patient's best interests, and it should proceed without delay. (Agreement: 100%, Evidence grade: D, Strength of recommendation: strong)

   *An example consent form is given in Appendix 2c – its use is optional.

3. The use of a PIL is advised.* (Agreement: 93%, Evidence grade: C, Strength of recommendation: strong)

   *An example of a PIL is given in Appendix 2b.

4. Radiology departments should have a CT protocol* for investigating AAPP in pregnancy. The protocol may be tailored to the clinical question. (Agreement: 93%, Evidence grade: C, Strength of recommendation: strong)

   *Further information on the practice of CT in pregnancy is provided in Appendix 3b.

5. Intravenous contrast can be administered as it would be for the same clinical indication in a patient who is not pregnant. (Agreement: 100%, Evidence grade: D, Strength of recommendation: strong)

6. If intravenous contrast is required, the nominated member of the team should advise the patient that there is a theoretical risk of hypothyroidism and a heel prick test is advised at birth* (and that this is performed as part of routine neonatal screening in the UK). (Agreement: 100%, Evidence grade: A, Strength of recommendation: strong)

   *This information is included in the PIL and consent forms in Appendix 2b and 2c.

When CT is required, and the pregnant patient can consent, appropriate informed consent can be obtained, with time taken to discuss the issues of radiation exposure.

Because of the risk to the fetus the panel recommends that the clinical team discuss with the patient (or their advocate).[15,19,58,59] Documented consent is recommended (with optional use of a consent form), as is the use of a PIL (an example of which can be found in Appendix 2b).

03
How to deliver a service

Ultra-low-dose protocols are generally avoided in pregnant patients as they can be non-diagnostic, potentially leading to both a delay in diagnosis and further radiation exposure from additional imaging.[60,61] Single-phase contrast-enhanced CT should be used where possible to minimise fetal radiation exposure. Exceptions to this include suspected urinary tract injury and suspected active bleeding.[16] Dose-reduction techniques including organ dose modulation, reducing tube current/voltage and iterative reconstruction should be considered.[62] Specific guidance on CT optimisation techniques can be found in Appendix 3b.

CT uses iodinated contrast. The thyroid gland of the developing fetus is sensitive to iodine loads. Despite this, there is no evidence that the administration of CT contrast during pregnancy causes thyroid dysfunction in the neonate, and contrast agents are considered safe for use in pregnancy when clinically indicated.[63,64] Enteric contrast can also be used safely in pregnancy.[65] As part of standard neonatal care, thyroid function is routinely assessed within the first week of life, ensuring that any abnormality, whether or not related to iodine exposure, is detected and appropriately managed.[2,11,48,63,66]

7. Abdominal shielding should be avoided. (Agreement: 93%, Evidence grade: B, Strength of recommendation: strong)

Historically, abdominal lead shielding was sometimes used in imaging studies involving ionising radiation when the fetus was not directly within the primary beam. However, as the predominant source of fetal radiation dose in such procedures is internal scatter rather than direct exposure, the use of abdominal shielding is unlikely to provide meaningful dose reduction. Furthermore, inadvertent placement of shielding within the imaging field may trigger automatic exposure control mechanisms, potentially resulting in increased radiation dose. Current guidelines from the American College of Radiology and Society of Paediatric Radiology, American Association of Physicists in Medicine, European Society of Radiology and Society of Radiographers, and British consensus guidelines advise against the routine use of lead shielding.[14,67,68,69]

Plain radiography

1. Abdominal radiograph is rarely indicated and should only be considered in specific clinical scenarios. (Agreement: 100%, Evidence grade: A, Strength of recommendation: strong)
2. Abdominal shielding should be avoided. (Agreement: 100%, Evidence grade: B, Strength of recommendation: strong)

See ‘Suspected acute small or large bowel pathology (excluding appendicitis)’ and ‘CT’. Abdominal radiographs are considered under specific circumstances, but generally avoided.[70,71] Abdominal shielding should be avoided as above.[68]

03
How to deliver a service

Service provision and training

1. Radiology services should develop ultrasound and MRI imaging for assessment of AAPP in pregnancy. (Agreement: 100%, Evidence grade: D, Strength of recommendation: strong)
2. Radiology training should include imaging pathways to assess AAPP in pregnancy and interpretation of ultrasound and MRI in this context. (Agreement: 100%, Evidence grade: D, Strength of recommendation: strong)

The panel emphasises that the availability and ease of CT do not justify its use in AAPP in pregnancy when ultrasound or MRI are available/appropriate alternatives. Resources and training should be directed towards expanding access and developing expertise in non-ionising imaging, given the risks to the fetus associated with ionising radiation.

In the BSUR–BSGAR AAPP in pregnancy UK survey, respondents reported variation in who interprets MRI for AAPP in pregnancy, with the most common responses being: 'any available consultant radiologist' (23%), 'provisionally reporting radiologist in training' (11%), 'gastrointestinal radiologist' (19%), 'genitourinary radiologist' (15%) and 'outsourcing company' (7%).[4] This indicates that interpreting MRI in AAPP in pregnancy requires input from radiologists across a range of subspecialties. Although MRI use for AAPP in pregnancy is currently limited, it is expected to become more common as access improves. Although radiology reporting networks may help in the future, the panel advises radiology departments and training programmes to plan proactively. This may have implications for trainee education and could be integrated into existing abdominal radiology rotations.

Access to ultrasound, particularly specialist bowel ultrasound, may be limited; the panel therefore recommends national upskilling to improve accessibility. Further guidance is beyond the remit of this document.

04 Discussion

These guidelines aim to address a longstanding gap in UK practice by providing nationally agreed recommendations for imaging AAPP in pregnancy. Previously, practice varied widely, often relying on local custom or extrapolation from non-pregnant populations, leading to diagnostic delays and inconsistent care. By combining available evidence with expert consensus, this document aims to offer a pragmatic framework aligned with contemporary UK/NHS practice.

A key principle underpinning the consensus is that maternal health takes precedence, as it is integral to fetal wellbeing. The guidance prioritises non-ionising imaging, while recognising that CT and other ionising studies may be necessary in acute settings where delay would compromise outcomes. In such cases, radiation risks should be clearly communicated without unduly delaying urgent imaging.

The guideline acknowledges variability in service provision, particularly out of hours, and highlights the need for practical solutions such as standardised MRI protocols and accessible patient information. Recommendations on radiologist supervision are aspirational, reflecting current UK/NHS constraints while emphasising the value of senior clinical input. The distinction between maternal and fetal imaging is also clarified, supporting confident imaging for maternal pathology with appropriate referral when fetal assessment is required.

This represents the first UK consensus jointly developed by the RCR, BSUR and BSGAR in this area, aiming to standardise practice and support clinicians managing complex scenarios, while recognising the ongoing need for service development and training.

05 Conclusion

Imaging plays a central role in the diagnosis of acute abdominal and pelvic pathology in pregnancy, yet variation in practice and safety concerns continue to challenge clinicians. These guidelines provide an evidence-based framework to support safe, timely and consistent imaging across the UK/NHS, emphasising maternal health, preferential use of non-ionising modalities and judicious use of CT when indicated. Standardised protocols, multidisciplinary working and appropriate senior input are key to improving diagnostic accuracy and outcomes.

The panel intends for these guidelines to empower radiologists and clinical teams to approach imaging of pregnant patients with acute abdominal and pelvic presentations with confidence rather than apprehension.

06 Acknowledgements

Georgina Blenkinsopp, Krista Gelder, Dileep Wijeratine, the RCR i-Refer team, the RCR Professional Practice Board.

A1 Literature search

A systematic literature review was performed in PubMed and Ovid (including OvidMedline + EMBASE classic) and Cochrane searching title and abstract using the search terms: pregnan* OR obstetric AND abdom* AND 'Computed tomography' OR CT OR MRI OR 'magnetic resonance imaging' OR 'ultrasound' OR 'plain film' OR radiograph* OR x-ray OR contrast OR imaging.

Search terms were formed following an initial review of the literature. Included were manuscripts published in English from 2000 until the date of the literature search, limited to human studies with abstract available. Filters were applied to search the following publications: Abstract, Books and Documents, Classical Article, Clinical Study, Clinical Trial, Comparative Study, Controlled Clinical Trial, Evaluation Study, Government Publication, Guideline, Legislation, Meta-Analysis, Multicenter Study, Observational Study, Practice Guideline, Randomized Controlled Trial, Review, Systematic Review.

The literature search was performed on 3 February 2025 and updated on 20 March 2025. The titles of the manuscripts identified by the literature search were reviewed for relevance by Rachel Gravell, and those that appeared suitable were reviewed in further detail. The included manuscripts were then disseminated to the panel to aid the formulation of the guidelines.

A2a Example patient information leaflet – MRI

MRI

Information for pregnant patients undergoing an MRI scan

What is an MRI scan?

MRI stands for magnetic resonance imaging. It is a safe, non-invasive scan that uses strong magnetic fields and radio waves to produce detailed images of the inside of your body. MRI does not use any X-ray radiation, unlike X-rays or CT (computed tomography) scans.

Why might I need an MRI scan during pregnancy?

If you become unwell during pregnancy, your medical team may need detailed images to help understand what is happening and how best to treat you. MRI can provide important information that other scans, like ultrasound, may not be able to show clearly.

Is an MRI scan safe for pregnant people?

Yes, MRI is safe during pregnancy. Before the scan, radiographers will ask you some routine questions and perform standard safety checks – like checking for metal implants – to make sure the MRI is safe for you. These checks are the same for all patients and are not specific to pregnancy.

Is an MRI scan safe for the unborn baby?

Yes, MRI is safe during pregnancy. There is no evidence it harms you or your unborn baby, and it's not linked to birth defects, growth issues or hearing problems. While there are some theoretical risks, your medical and radiology team will only recommend an MRI if it's necessary for your care. If possible, they may wait until after the first trimester but won't delay it if waiting could risk your health.

The theoretical risks are explained below.

- **Magnetic field:** The MRI scanner uses a very powerful magnetic field. There is no evidence to suggest that this poses any risk to the unborn baby.
- **Heating:** The scanner can have a heating effect, and it uses height and weight calculations to keep this heating to a minimum. As a safety precaution, radiographers closely monitor the heating effect of the scan, known as the specific absorption rate (SAR), to ensure it remains within safe limits throughout the procedure.
- **Noise:** During the scan, you will hear loud knocking or tapping sounds. These sounds come from electrical currents switching on and off to help produce the images and it is completely normal. There is no evidence to suggest there is any risk to the unborn baby from this noise during pregnancy.

A2a

Appendix 2a

What should I expect during the scan?

Once all the safety checks have been completed, you will be asked to change into a hospital gown and store your belongings securely in a locker during the scan.

You will lie on a padded table that gently moves into the MRI scanner. The scan usually takes between 20 and 45 minutes, depending on the area being examined. It is important to stay as still as possible throughout to ensure clear images.

The scanner makes loud tapping or knocking sounds, but you will be given earplugs or headphones to reduce the noise (you can also listen to music if you wish). You can speak to the radiographers at any time through an intercom, and they will monitor you throughout.

If lying flat is uncomfortable, you can lie on your side with plenty of cushions for support. Please let us know your preference – we want to make you as comfortable as possible.

If you feel anxious or claustrophobic, tell the radiographers before or during the scan. They will talk you through options to help you feel more at ease. Your comfort and safety are the priority.

Who can I talk to if I have questions or concerns?

If you have questions or concerns about your MRI, please speak to any member of the team caring for you, or the radiology team. They are here to support you in making informed decisions about your care.

A2b Example patient information leaflet – CT

X-ray radiation exposure during a CT scan

Information for pregnant patients undergoing a CT scan

This leaflet is designed to help you make an informed decision about having a CT (computed tomography) scan, by clearly explaining the benefits and risks.

What is a CT scan?

CT is a type of scan that uses X-ray radiation to take detailed images of the inside of your body. It can help your medical team quickly make a diagnosis and plan the best treatment.

Why might I need a CT scan during pregnancy?

If you become unwell during pregnancy, your medical team may need detailed images to help understand what is happening and how best to treat you. CT scans are only used during pregnancy when they are the safest and most effective way to get the information needed.

Whenever possible, other types of scans that do not use X-ray radiation, such as ultrasound or MRI (magnetic resonance imaging), will be considered first. However, if a CT scan is considered the best option, your medical team will explain the reasons for this and discuss the potential risks and benefits with you. You will have the opportunity to ask questions and share any concerns, so that together you can decide whether to go ahead with the scan.

Is a CT scan safe for pregnant people?

The CT scan generally carries very low risks. The main concern is exposure to a small amount of X-ray radiation, which is usually not harmful when only one scan is done. During pregnancy, the breast tissue is more sensitive to X-ray radiation, which could very slightly increase the risk of breast cancer. We don't know the exact size of this risk, but it is thought to be very small and is usually considered to be outweighed by the benefits of having the scan.

Is a CT scan safe for the unborn baby?

There are some risks related to X-ray radiation exposure, but these will have been carefully weighed against the benefits before recommending the scan.

A2b

Appendix 2b

X-ray radiation exposure

During a CT scan, your unborn baby will be exposed to a very small amount of X-ray radiation. This amount is too low to cause miscarriage, birth defects or problems with your baby's growth or development.

There is a very small increase in the chance of your child developing cancer later in life. However, this risk is very low, and every effort is made to keep your unborn baby's exposure to X-ray radiation as low as possible.

X-ray radiation is measured in units called milligray (mGy). According to UK National guidelines* each 1 mGy of X-ray radiation may increase the risk of childhood cancer by approximately 1 in 10,000 (or 0.01%). To put this into perspective, about 1 in 500 children (0.2%) develop childhood cancer naturally, without any exposure to medical scans that involve X-ray radiation. This natural chance is known as the background risk.

How much X-ray radiation is involved in different CT scans?

The amount of X-ray radiation your unborn baby is exposed to depends on the type of scan and stage of pregnancy. The estimated additional risk of childhood cancer also varies, but it remains very low, even for larger scans.

Type of CT scan	Fetal dose (mGy)	Estimated additional risk of cancer
CT abdomen (not including pelvis)	1–10	1 in 10,000 to 1 in 1,000*
CT abdomen and pelvis CT whole body (trauma scan)	10–50	1 in 1,000 to 1 in 200*

Notes

Fetal dose is the estimated amount of X-ray radiation the unborn baby is exposed to during the scan.

*From Protection of pregnant patients during diagnostic medical exposures to ionising radiation, produced by the Health Protection Agency, The Royal College of Radiologists and The Royal College of Radiographers.

Are there any alternative scans I could have?

Yes. Some scans, like ultrasound or MRI, do not use X-ray radiation. However, they are not always suitable for diagnosing certain conditions. Your medical team will always consider these alternatives first and will only recommend a CT scan if it is the best option for you and your unborn baby.

Can a shield be used to protect my unborn baby from radiation?

In the past, lead aprons or shields were sometimes used to protect the unborn baby during scans. However, current UK and international guidance does not recommend routine shielding during CT scans in pregnancy.

Modern scanners are designed to limit radiation very precisely. Using a shield can sometimes interfere with the scan or even increase the overall radiation dose.

A2b

Appendix 2b

What about the contrast dye sometimes used in CT scans?

Some CT scans use an injection of dye into a vein (called contrast) to make the images clearer. There is no actual evidence that this dye harms your unborn baby.

However, due to a theoretical risk of causing hypothyroidism, as a precaution your baby's thyroid function (a gland in the neck that controls growth and development) should be checked in the first week after birth. This is just to make sure everything is normal. This is already offered as part of routine neonatal screening in the UK and so will not involve an extra test for your baby. If there is a problem – which is very rare – it can be treated easily and early.

What should I expect during the CT scan?

Once the safety checks have been completed, you may be asked to change into a hospital gown and store your belongings securely in a locker during the scan.

You will lie on a padded table that gently moves into the CT scanner, which is a large, round, doughnut-shaped machine.

The scan usually takes a few minutes, depending on the area being checked.

It's important to stay as still as possible to ensure clear images.

The machine will make some buzzing or whirring noises while it works.

Sometimes, you may be asked to hold your breath for a few seconds.

If lying flat is uncomfortable, you can lie on your side with plenty of cushions for support. Please let us know your preference – we want to make you as comfortable as possible.

You might have a small injection of dye into your vein. Your medical team will tell you if this is needed.

You can talk to the medical team through a microphone if you feel uncomfortable or have any questions during the scan.

The medical team will watch over you the whole time to keep you safe and comfortable.

Who can I talk to if I have questions or concerns?

If you have questions or concerns about your CT scan, please speak to any member of the team caring for you, or the radiology team. They are here to support you in making informed decisions about your care.

A2C Example patient consent form for CT imaging in pregnancy

Patient information

Name	
Date of birth	
Hospital number	
NHS number	

Statement of health professional

To be completed by a health professional with appropriate knowledge of the proposed procedure.

I have explained the procedure to the patient. In particular, I have explained the following.

The intended benefits

The CT scan aims to provide valuable diagnostic information that could be crucial for managing your health during pregnancy.

The significant, unavoidable or frequently occurring risks

This investigation may slightly increase the chances of your unborn baby developing cancer later in their life. However, the risk is very small. The scan will not add to risks of miscarriage or problems with your unborn baby's growth or development.

During pregnancy, your breast tissue is more sensitive to X-ray radiation, which could very slightly increase the risk of breast cancer if the CT scan involves imaging the chest area. We don't know the exact size of this risk (it is a theoretical risk), but it is thought to be very small.

Some CT scans use an injection of contrast dye into your vein to make the images clearer. There is no actual evidence that this dye harms your unborn baby. However, due to a theoretical risk of causing hypothyroidism, as a precaution, your baby's thyroid function should be checked in the first week after birth. This is already offered as part of routine neonatal screening in the UK and so will not involve an extra test for your baby. If there is a problem – which is very rare – it can be treated easily and early.

A2c

Appendix 2c

I have discussed what the procedure is likely to involve, the benefits and risks of any available alternative treatments (including no treatment) and any particular concerns of this patient.

The following patient information leaflet has been provided	
Signed	
Name (PRINT)	
Job title	
Date	

Statement of interpreter (where appropriate)

I have interpreted the information above to the patient to the best of my ability and in a way in which I believe the patient can understand.

Signed	
Name (PRINT)	
Job title	
Date	

Statement of patient

I acknowledge that I have been informed of the potential risks and benefits of undergoing a CT scan during pregnancy. I understand that while the healthcare provider will make every effort to minimise X-ray radiation exposure, there may still be associated risks.

I have had the opportunity to ask questions about the procedure, its risks and alternatives, and all my questions have been answered to my satisfaction. I understand that I can withdraw my consent at any time without affecting the quality of care I receive.

I agree to the procedure as described on this form.

Patient's signature	
Name (PRINT)	

Please read this form carefully. If you have any further questions, please ask – we are here to help. You have the right to change your mind at any time, including after you have signed this form.

A3a Suggested MRI protocol for AAPP in pregnancy

General protocol

This is a comprehensive MRI protocol designed to investigate most causes of AAPP in pregnancy.

Sequence	Plane	Area covered
T2 Suggest single-shot fast spin echo*	Axial/coronal/sagittal	Abdomen/pelvis
T2 Suggest single-shot fast spin echo*	Sagittal	Pelvis (to cover whole uterus, cervix and vagina if possible)
T2 with fat suppression Suggest single-shot fast spin echo*	Axial	Abdomen/pelvis
Balanced steady-state free precession (bSSFP)*	Axial/coronal	Abdomen/pelvis
T1 and T1 with fat suppression or T1 DIXON	Axial	Abdomen/pelvis
DWI + ADC map Two B values: 0 or 50 and 800 or 1,000	Axial or coronal	Abdomen/pelvis

*Vendor-specific sequence names.

Generic sequences name	Siemens	GE	Philips	Canon/ Toshiba	Hitachi
SSFSE	HASTE	SSFSE	SSh-TSE	SSFSE/FASE	SS-FSE
bSSFP	TRUFI/TrueFISP	FIESTA,COSMIC	Balanced FFE	True SSFP	BASG or SARGE

A3a

Appendix 3a

Supervision and sequence selection

It is recommended that the MRI scan be supervised by a radiologist. With radiologist oversight, the study may be terminated early if the relevant pathology is identified or the clinical question has been satisfactorily answered.

Patients should be offered the option to lie in the lateral decubitus position, especially later in pregnancy, to improve comfort.

When appropriate, consider beginning with the sequences most likely to reveal the suspected pathology. For example:

- Gynaecological pathology may be best demonstrated on sagittal and axial T2-weighted sequences.
- Bowel pathology may be best demonstrated using coronal T2 and axial T2 with fat suppression sequences.

Additional sequences (as indicated)

Depending on clinical suspicion, the following additional sequences may be helpful:

- Suspected urinary tract pathology: add MR urography.
- Suspected biliary or liver pathology: add MRCP.

A3b Practical considerations for CT in AAPP in pregnancy

General principles

No single CT protocol is recommended because of variations in scanners and patient factors. The principles outlined above – considering alternative imaging, ensuring patient counselling and consent, appropriate use of contrast and avoiding shielding – should be followed. While input from medical physics is valuable when available, it should not delay urgent imaging.

Scanner familiarity

- Use the newest scanner with the lowest local diagnostic reference levels (LDRLs).
- Understand your automatic exposure control (AEC) system; adjust as appropriate.
- Position the patient at the isocentre for optimal AEC performance.

Protocol optimisation

- Enable organ dose modulation.
- Reduce tube current/voltage (eg CAREdose, CAREkV) if appropriate.
- Use iterative reconstruction (IR) to reduce dose or improve image quality.
- Avoid multiphase or repeat scans; trauma protocols can achieve arterial and venous imaging in a single acquisition by use of a split bolus technique.
- Refer to your local image optimisation team and medical physics department.

References

1 Casciani E, Masselli G, Luciani ML, Polidori NF, Piccioni MG, Gualdi G. Errors in imaging of emergencies in pregnancy. *Semin Ultrasound CT MR* 2012; **33**(4): 347–70.

2 Chirag J. Guidelines for diagnostic imaging during pregnancy and lactation. ACOG Committee Opinion 723. *Obstet Gynecol* 2017; **130**: e210–6. www.acog.org/clinical/clinical-guidance/committee-opinion/articles/2017/10/guidelines-for-diagnostic-imaging-during-pregnancy-and-lactation

3 Zachariah SK, Fenn M, Jacob K, Arthungal SA, Zachariah SA. Management of acute abdomen in pregnancy: current perspectives. *Int J Women's Health* 2019; **11**: 119–34.

4 Wiles R, Cuthbert F, Balasubramaniam R, Pakpoor J, Withey S. Imaging acute abdominal presentations in pregnancy: a British Society of Urogenital Radiology and British Society of Gastrointestinal and Abdominal Radiology survey of UK radiology practice. *Clin Radiol* 2026; **107366**.

5 The ESGAR Research Committee. ESGAR guidelines for development of consensus guidelines. ESGAR, 2024. https://esgar.org/fileadmin/media/Research/Guideline_development_guidelines_2024_update.pdf

6 Fitch K, Bernstein S, Aguilar M *et al*. *The RAND/UCLA appropriateness method user's manual*. AHCPR Pub. No. 95-0009. Rockville, MD: Public Health Service, US Department of Health and Human Services, 2001.

7 Brouwers MC, Kho ME, Browman GP *et al*. AGREE II: advancing guideline development, reporting and evaluation in health care. *CMAJ* 2010; **182**(18): E839–42.

8 Agree Consortium. Appraisal of guidelines for research & evaluation II. Agreetrust.org, 2017. www.agreetrust.org/wp-content/uploads/2017/12/AGREE-II-Users-Manual-and-23-item-Instrument-2009-Update-2017.pdf

9 Howick J, Chalmers I (James Lind Library), Glasziou P *et al*. The Oxford 2011 levels of evidence. OCEBM Levels of Evidence Working Group, 2011. www.cebm.net/index.aspx?o=5653

10 Atkins D, Best D, Briss PA *et al*. Grading quality of evidence and strength of recommendations. *BMJ* 2004; **328**(7454): 1490.

11 Wiles R, Hankinson B, Benbow E, Sharp A. Making decisions about radiological imaging in pregnancy. *BMJ* 2022; **377**: e070486.

12 Masselli G, Brunelli R, Monti R *et al*. Imaging for acute pelvic pain in pregnancy. *Insights Imaging* 2014; **5**(2): 165–81.

13 Wieseler KM, Bhargava P, Kanal KM, Vaidya S, Stewart BK, Dighe MK. Imaging in pregnant patients: examination appropriateness. *Radiographics* 2010; **30**(5): 1215–29; discussion 1230–3.

14 American College of Radiology (ACR) and Society for Pediatric Radiology (SPR). ACR-SPR practice parameter for imaging pregnant or potentially pregnant patients with ionizing radiation. Revised 2023 (Resolution 31). Reston, VA: American College of Radiology, 2023.

15 Tirada N, Dreizin D, Khati NJ, Akin EA, Zeman RK. Imaging pregnant and lactating patients. *Radiographics* 2015; **35**(6): 1751–65.

16 Goldberg-Stein SA, Liu B, Hahn PF, Lee SI. Radiation dose management: part 2, estimating fetal radiation risk from CT during pregnancy. *AJR Am J Roentgenol* 2012; **198**(4): W352–6.

17 Health Protection Agency, The Royal College of Radiologists and The Royal College of Radiographers. *Protection of pregnant patients during diagnostic medical exposures to ionising radiation*. London: The Royal College of Radiologists, 2009. www.rcr.ac.uk/our-services/all-our-publications/clinical-radiology-publications/protection-of-pregnant-patients-during-diagnostic-medical-exposures-to-ionising-radiation

18 International Commission on Radiological Protection. Pregnancy and medical radiation. ICRP Publication 84. International Commission on Radiological Protection, 2000.

19 Lie G, Eleti S, Chan D, Roshen M, Cross S, Qureshi M. Imaging the acute abdomen in pregnancy: a radiological decision-making tool and the role of MRI. *Clin Radiol* 2022; **77**(9): 639–49.

20 Ray JG, Vermeulen MJ, Bharatha A, Montanera WJ, Park AL. Association between MRI exposure during pregnancy and fetal and childhood outcomes. *JAMA* 2016; **316**(9): 952.

21 Newnham JP, Doherty DA, Kendall GE, Zubrick SR, Landau LL, Stanley FJ. Effects of repeated prenatal ultrasound examinations on childhood outcome up to 8 years of age: follow-up of a randomised controlled trial. *Lancet* 2004; **364**(9450): 2038–44.

22 Newnham JP, Sharon SF, Michael CA, Stanley FJ, Landau LI. Effects of frequent ultrasound during pregnancy: a randomised controlled trial. *Jordemodern* 1994; **107**(3): 83–6.

23 The Ionising Radiation (Medical Exposure) (Amendment) Regulations 2024.

24 Giles D, Hewitt D, Stewart A, Webb J. Malignant disease in childhood and diagnostic irradiation in utero. *Lancet* 1956; **271**(6940): 447.

25 Bithell JF, Stewart AM. Pre-natal irradiation and childhood malignancy: a review of British data from the Oxford Survey. *Br J Cancer* 1975; **31**(3): 271–87.

26 Lowe S. Diagnostic imaging in pregnancy: making informed decisions. *Obstet Med* 2019; **12**(3): 116–22.

27 Dhamecha R, Pajai S, Bhasin T. Acute abdomen in pregnancy: a comprehensive review of diagnosis and management. *Cureus* 2023; **15**(6): e40679.

28 Puris G, Chetrit A, Katorza E. Fetal safety in MRI during pregnancy: a comprehensive review. *Diagnostics (Basel)* 2025; **15**(2): 208.

29 Saleem SN. Fetal MRI: an approach to practice – a review. *J Adv Res* 2014; **5**(5): 507–23.

30 The Royal College of Radiologists. *Standards for interpretation and reporting of imaging investigations*. London: The Royal College of Radiologists, 2018.

31 European Trauma Course Organisation. Chapter 6b: trauma in pregnancy or as a result of domestic violence. *European trauma course manual,* 4th edition. European Trauma Course Organisation, 2018.

32 MacDermott R, Berger FH, Phillips A *et al*. Initial imaging of pregnant patients in the trauma bay: discussion and review of presentations at a level-1 trauma centre. *Diagnostics (Basel)* 2024; **14**(3): 276.

33 April MD, Long B. Trauma in pregnancy: a narrative review of the current literature. *Am J Emerg Med* 2024; **81**: 53–61.

34 Sadro C, Bernstein MP, Kanal KM. Imaging of trauma: part 2, abdominal trauma and pregnancy – a radiologist's guide to doing what is best for the mother and baby. *AJR Am J Roentgenol* 2012; **199**(6): 1207–19.

35 American College of Surgeons. Trauma in pregnancy and intimate partner violence. In *Advanced Trauma Life Support (ATLS) student course manual, 10th edition*. Chicago, IL: American College of Surgeons, 2018.

36 Young L, Barnard C, Lewis E *et al*. The diagnostic performance of ultrasound in the detection of ectopic pregnancy. *N Z Med J* 2017; **130**(1452): 17–22.

37 Nagenthran G, Rangasami R, Chandrasekharan A, Soundararajan P, Godla UR. Role of magnetic resonance imaging in pregnancy-associated obstetric and gynecological complications. *Egypt J Radiol Nucl Med* 2019; **50**(1). https://doi.org/10.1186/s43055-019-0112-x

38 Bonito G, Masselli G, Gigli S, Ricci P. Imaging of acute abdominopelvic pain in pregnancy and puerperium – part I: obstetric (non-fetal) complications. *Diagnostics (Basel)* 2023; **13**(18). https://doi.org/10.3390/diagnostics13182890

39 Jha P, Melendres G, Bijan B *et al*. Trauma in pregnant women: assessing detection of post-traumatic placental abruption on contrast-enhanced CT versus ultrasound. *Abdom Radiol (NY)* 2017; **42**(4): 1062–7.

40 Wang Z, Bao F, Liang W *et al*. Appendicitis in pregnant women: a systematic review and meta- analysis of the diagnostic performance of ultrasonography. *J Clin Ultrasound* 2023; **51**(9): 1492–501.

41 Moghadam MN, Salarzaei M, Shahraki Z. Diagnostic accuracy of ultrasound in diagnosing acute appendicitis in pregnancy: a systematic review and meta-analysis. *Emerg Radiol* 2022; **29**(3): 437–48.

42 Motavaselian M, Bayati F, Amani-Beni R *et al*. Diagnostic performance of magnetic resonance imaging for detection of acute appendicitis in pregnant women: a systematic review and meta-analysis. *Arch Acad Emerg Med* 2022; **10**(1): e81.

43 Arruzza E, Milanese S, Li LSK, Dizon J. Diagnostic accuracy of computed tomography and ultrasound for the diagnosis of acute appendicitis: a systematic review and meta-analysis. *Radiography (Lond)* 2022; **28**(4): 1127–41.

44 Taylor SA, Mallett S, Bhatnagar G *et al*. Diagnostic accuracy of magnetic resonance enterography and small bowel ultrasound for the extent and activity of newly diagnosed and relapsed Crohn's disease (METRIC): a multicentre trial. *Lancet Gastroenterol Hepatol* 2018; **3**(8): 548–58.

45 Beall DP, Fortman BJ, Lawler BC, Regan F. Imaging bowel obstruction: a comparison between fast magnetic resonance imaging and helical computed tomography. *Clin Radiol* 2002; **57**(8): 719–24.

46 Bourgioti C, Konidari M, Gourtsoyianni S, Moulopoulos LA. Imaging during pregnancy: what the radiologist needs to know. *Diagn Interv Imaging* 2021; **102**(10): 593–603.

47 The Royal College of Emergency Medicine. *Best practice guideline: management of suspected internal drug trafficker (SIDT)*. London: The Royal College of Emergency Medicine, 2020.

48 Masselli G, Derchi L, McHugo J *et al*. Acute abdominal and pelvic pain in pregnancy: ESUR recommendations. *Eur Radiol* 2013; **23**(12): 3485–500.

49 Appelbaum RD, Yorkgitis B, Rosen J *et al*. Trauma in pregnancy: a systematic review, meta-analysis, and practice management guideline from the Eastern Association for the Surgery of Trauma. *J Trauma Acute Care Surg* 2025; **99**(2): 298–309.

50 Torloni MR, Vedmedovska N, Merialdi M *et al*. Safety of ultrasonography in pregnancy: WHO systematic review of the literature and meta-analysis. *Ultrasound Obstet Gynecol* 2009; **33**(5): 599–608.

51 American College of Radiology. *ACR manual on MR safety*. American College of Radiology, 2026. www.acr.org/Clinical-Resources/Clinical-Tools-and-Reference/radiology-safety/mr-safety

52 Oto A, Srinivasan PN, Ernst RD, Chaljub G, Gei AF, Saade G. Magnetic resonance imaging of maternal diseases causing acute abdominal pain during pregnancy: a pictorial review. *J Comput Assist Tomogr* 2005; **29**(3): 408–14.

53 Bolejko A, Hagell P. Effects of an information booklet on patient anxiety and satisfaction with information in magnetic resonance imaging: a randomized, single-blind, placebo-controlled trial. *Radiography (Lond)* 2021; **27**(1): 162–7.

54 Furey EA, Bailey AA, Pedrosa I. Magnetic resonance imaging of acute abdominal and pelvic pain in pregnancy. *Top Magn Reson Imaging* 2014; **23**(4): 225–42.

55 European Society of Urogenital Radiology. *ESUR guidelines on contrast agents 10.0*. European Society of Urogenital Radiology, 2018. www.esur.org/wp-content/uploads/2022/03/ESUR-Guidelines-10_0-Final-Version.pdf

56 National Institute for Health and Care Excellence British National Formulary (NICE BNF). Hyoscine butylbromide. BNF, 2024. https://bnf.nice.org.uk/drugs/hyoscine-butylbromide.

57 Medicines and Healthcare Products Regulations Authority (MHRA). Hyoscine n-butylbromide buscopan ampoules 20MG/ML. MHRA, 2025. https://products.mhra.gov.uk/product/?product=BUSCOPAN%20AMPOULES%2020MG%2FML

58 American College of Radiology. ACR Committee on Drugs and Contrast Media. *ACR manual on contrast media*. American College of Radiology, 2026. www.acr.org/Clinical-Resources/Clinical-Tools-and-Reference/Contrast-Manual

59 American College of Radiology. ACR practice guideline for imaging pregnant or potentially pregnant adolescents and women with ionizing radiation. American College of Radiology, 2008.

60 Langdon JH, Chai N, Patel A *et al*. Imaging of trauma in pregnant patients. *Radiographics* 2025; **45**(10): e240043.

61 Qamar SR, Green CR, Ghandehari H *et al*. CETARS/CAR practice guideline on imaging the pregnant trauma patient. *Can Assoc Radiol J* 2024; **75**(4): 743–50.

62 Gudjónsdóttir J, Ween B, Olsen DR. Optimal use of AEC in CT: a literature review. *Radiol Technol* 2010; **81**(4): 309–17.

63 van Welie N, Portela M, Dreyer K *et al*. Iodine contrast prior to or during pregnancy and neonatal thyroid function: a systematic review. *Eur J Endocrinol* 2021; **184**(1): 189–98.

64 The Royal Australian and New Zealand College of Radiologists. *Iodinated contrast media guideline, v2.3*. Sydney: RANZCR, 2018. www.ranzcr.com/college/document-library/iodinated-contrast-guidelines-2016

65 Perelli F, Turrini I, Giorgi MG *et al*. Contrast agents during pregnancy: pros and cons when really needed. *Int J Environ Res Public Health* 2022; **19**(24): 16699.

66 Eastwood K-A, Mohan AR. Imaging in pregnancy. *Obstet Gynaecol* 2019; **21**(4): 255–62.

67 American Association of Physicists in Medicine (AAPM). *Position statement on the use of patient gonadal and fetal shielding*. AAPM, 2019.

68 Hiles P, Gilligan P, Damilakis J *et al*. European consensus on patient contact shielding. *Radiography (Lond)* 2022; **28**(2): 353–9.

69 British Institute of Radiology, Institute of Physics and Engineering in Medicine, Public Health England, The Royal College of Radiologists, Society and College of Radiographers, Society for Radiological Protection. *Guidance on using shielding on patients for diagnostic radiology applications*. British Institute of Radiology, 2020.

70 Albakri AA, Alzahrani MM, Alghamdi SH. Medical imaging in pregnancy: safety, appropriate utilization, and alternative modalities for imaging pregnant patients. *Cureus* 2024; **16**(2): e54346.

71 Denham G, Smith T, James D, McKiernan S, Evans T-J. Exploring the evidence–practice gap in the use of plain radiography for acute abdominal pain and intestinal obstruction: a systematic review and meta-analysis. *Int J Evid Based Healthc* 2020; **18**(2): 159–69.

The Royal College of Radiologists
63 Lincoln's Inn Fields
London, WC2A 3JW, UK

The Royal College of Radiologists
is a Charity registered with the
Charity Commission No 211540.

+44 020 7405 1282
enquiries@rcr.ac.uk
rcr.ac.uk

@RCRadiologists

The Royal College of Radiologists

The Royal College of Radiologists. *Imaging acute abdominal and pelvic presentations in pregnancy: Consensus guidelines from BSUR, BSGAR and the RCR*. London: The Royal College of Radiologists, 2026.

The Royal College of Radiologists is a Charity registered with the Charity Commission No. 211540

© The Royal College of Radiologists, November 2026.

This material has been produced by The Royal College of Radiologists (RCR) for use internally within the specialties of clinical oncology and clinical radiology in the United Kingdom. It is provided for use by appropriately qualified professionals, and the making of any decision regarding the applicability and suitability of the material in any particular circumstance is subject to the user's professional judgement.

While every reasonable care has been taken to ensure the accuracy of the material, RCR cannot accept any responsibility for any action taken, or not taken, on the basis of it. As publisher, RCR shall not be liable to any person for any loss or damage, which may arise from the use of any of the material. The RCR does not exclude or limit liability for death or personal injury to the extent only that the same arises as a result of the negligence of RCR, its employees, Officers, members and Fellows, or any other person contributing to the formulation of the material.